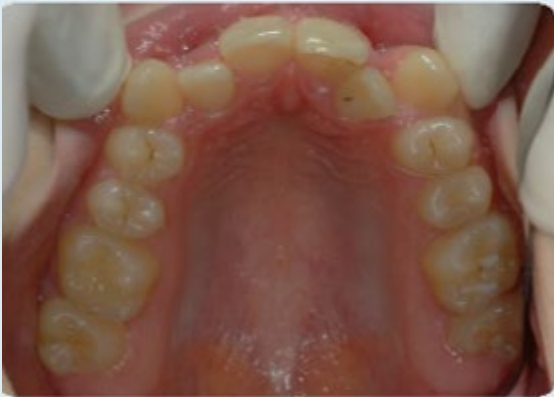
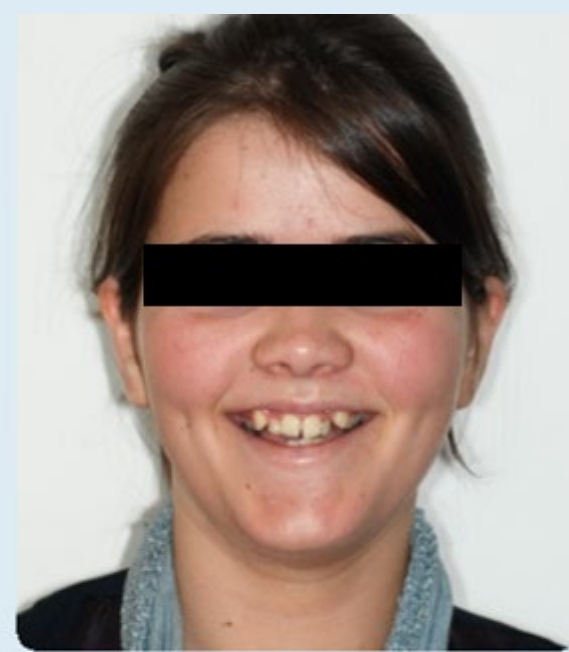
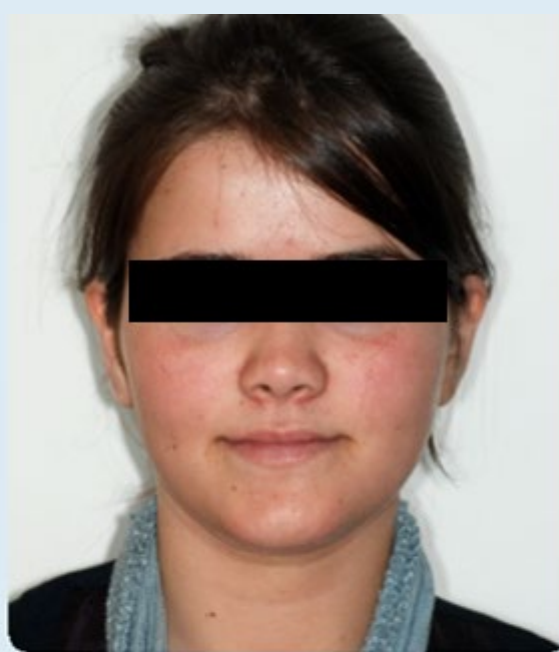
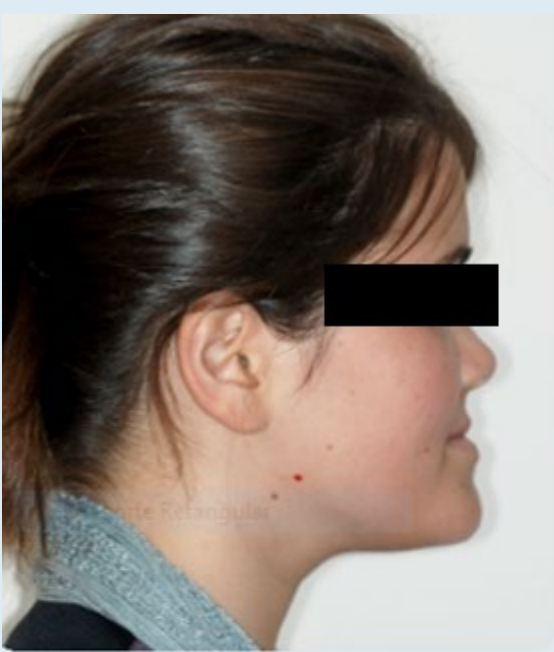
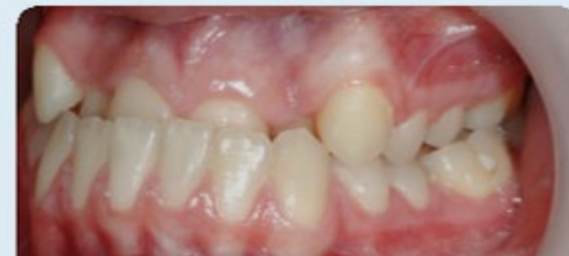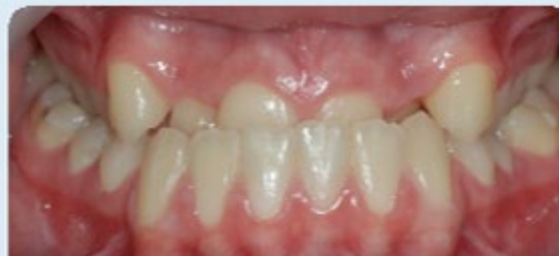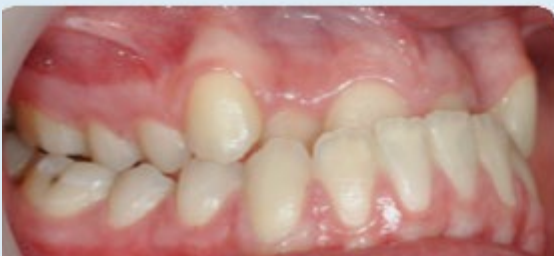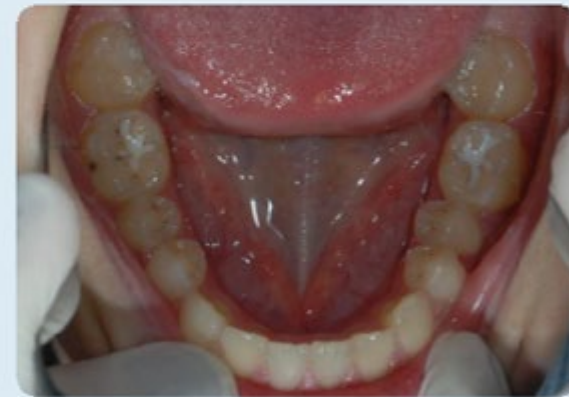Ortopóvoa

Caso de mordida  
cruzada anterior




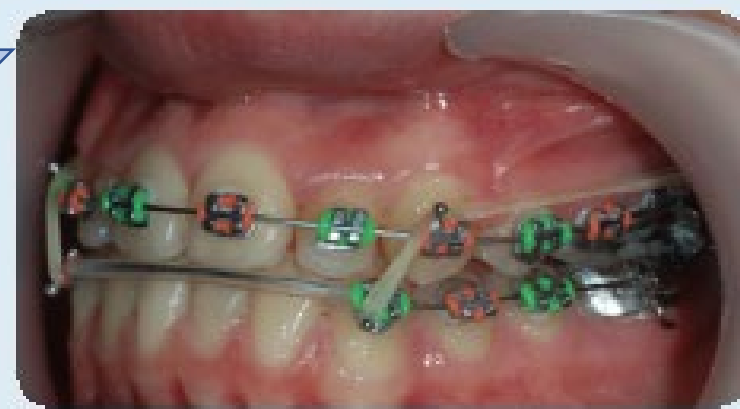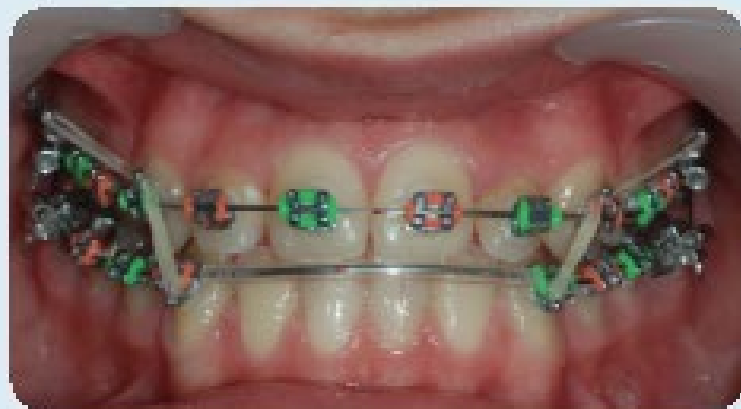
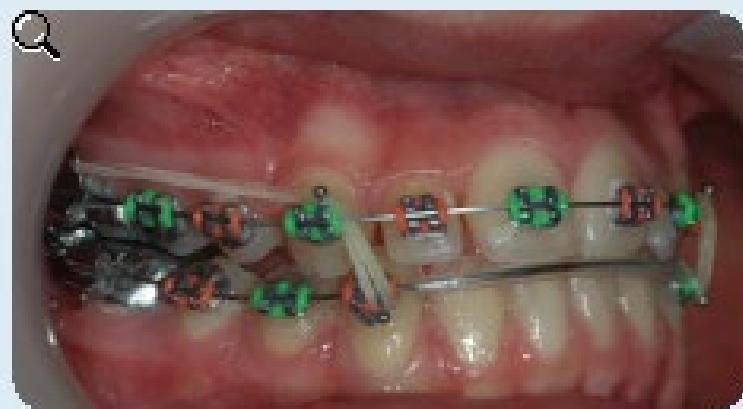
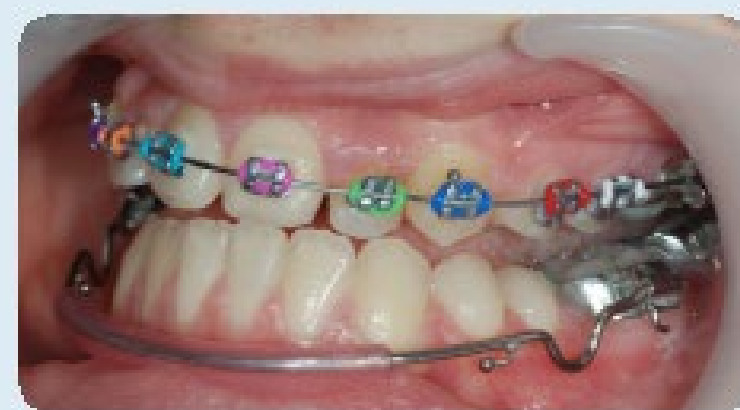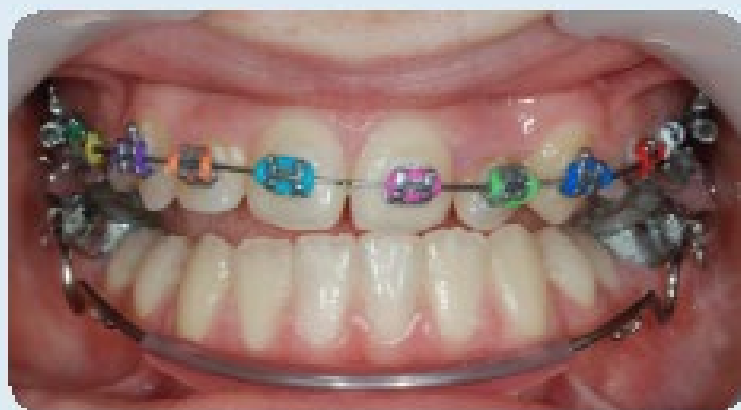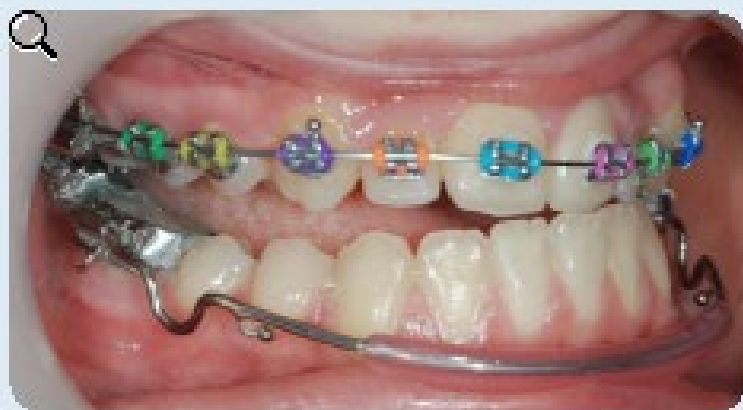
**Mordida cruzada anterior**

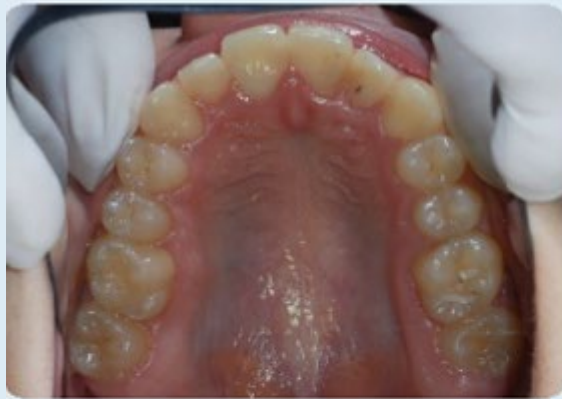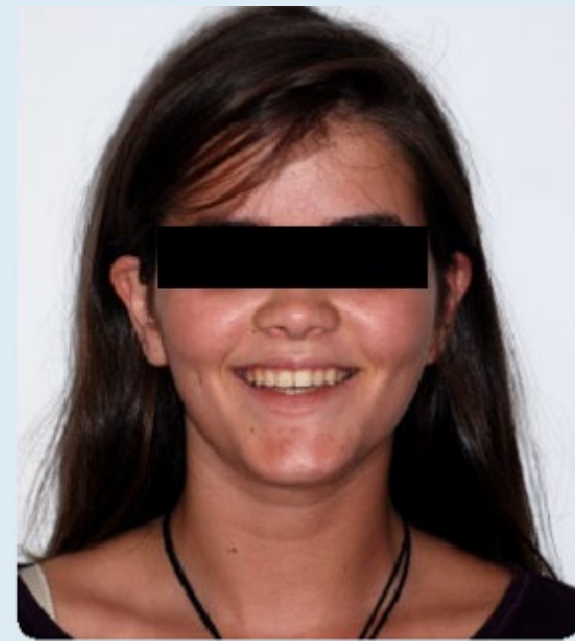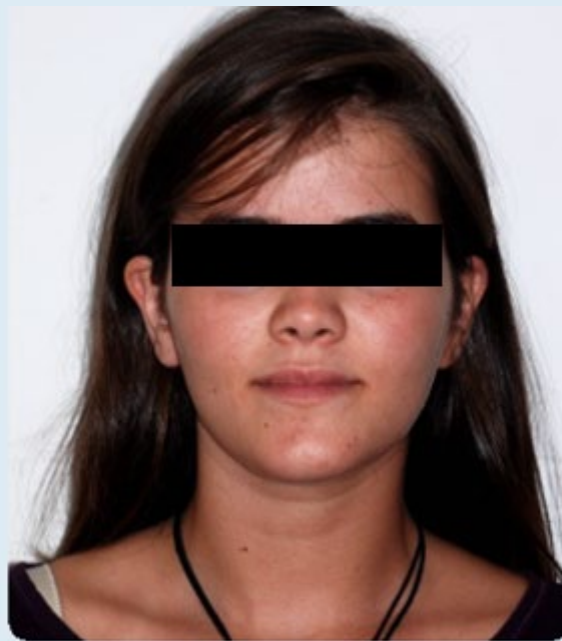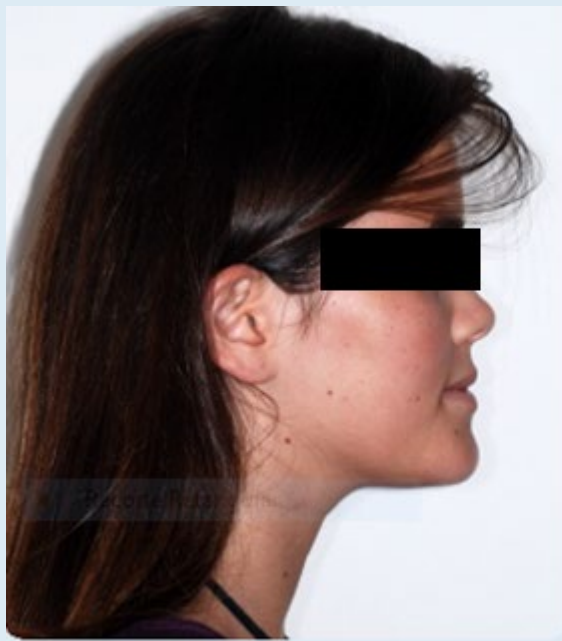**Inicial**



Mordida cruzada anterior

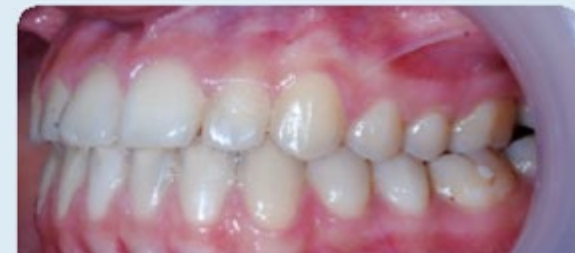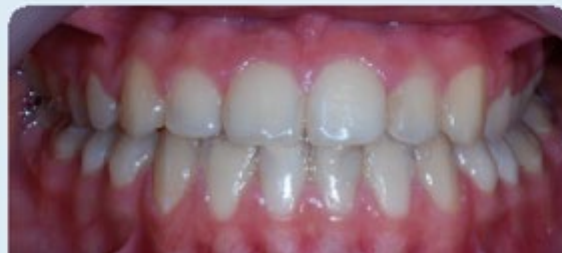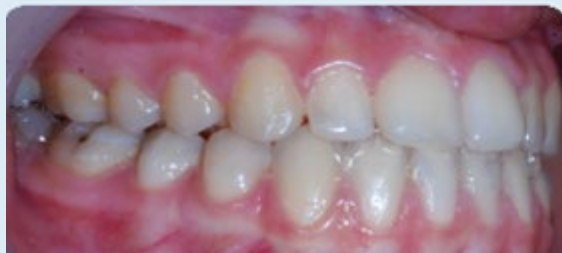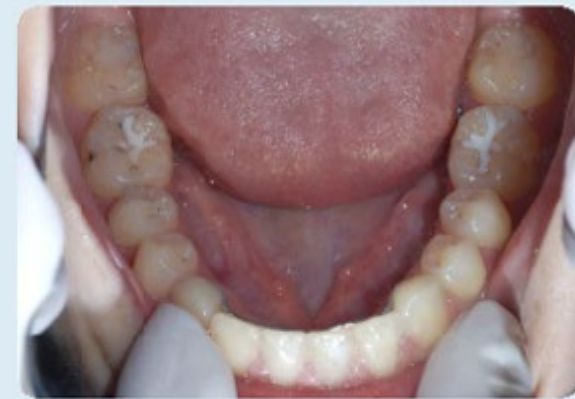Progreso






**Mordida cruzada anterior**

**Final**





**Mordida cruzada anterior**

2 años después del tratamiento

