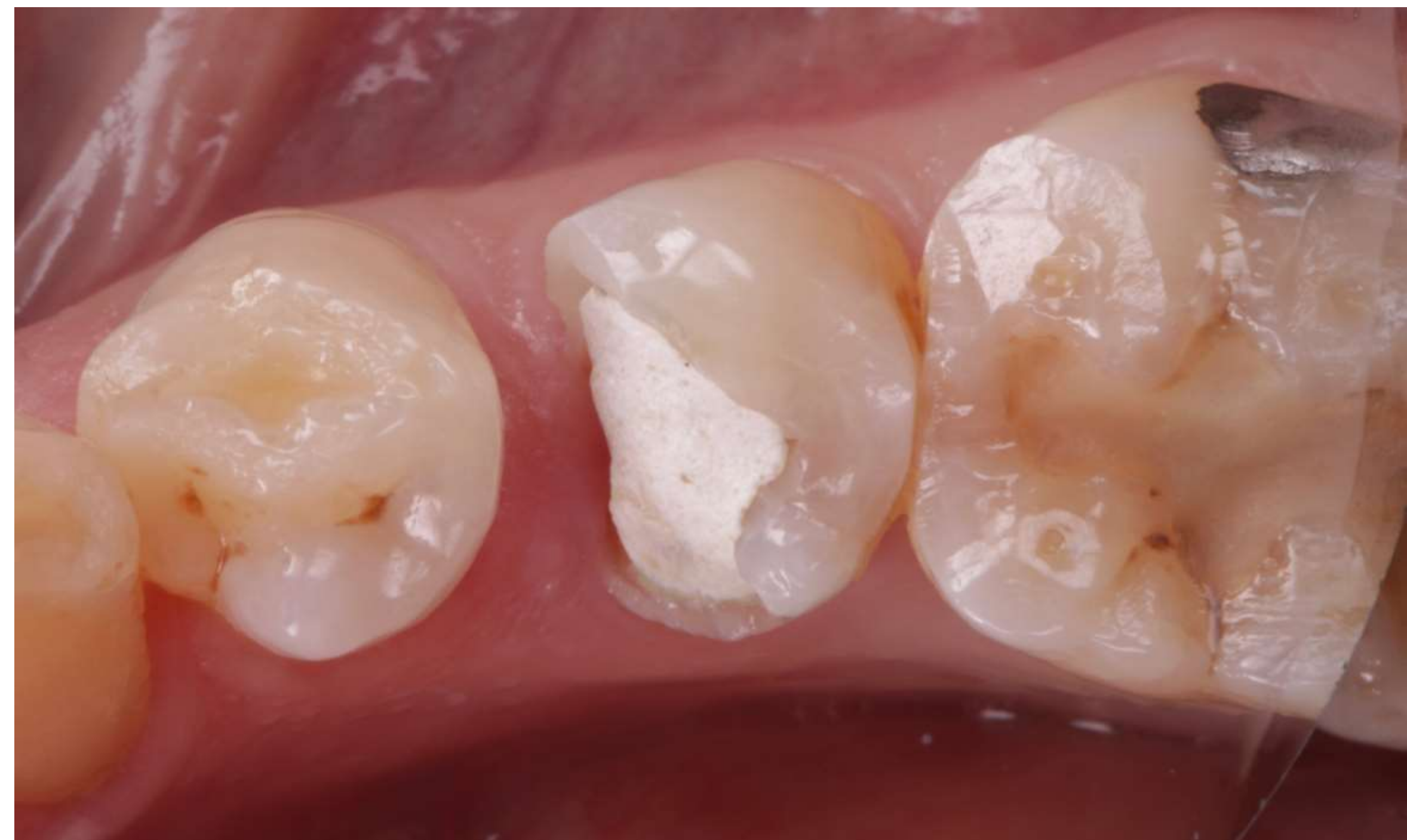
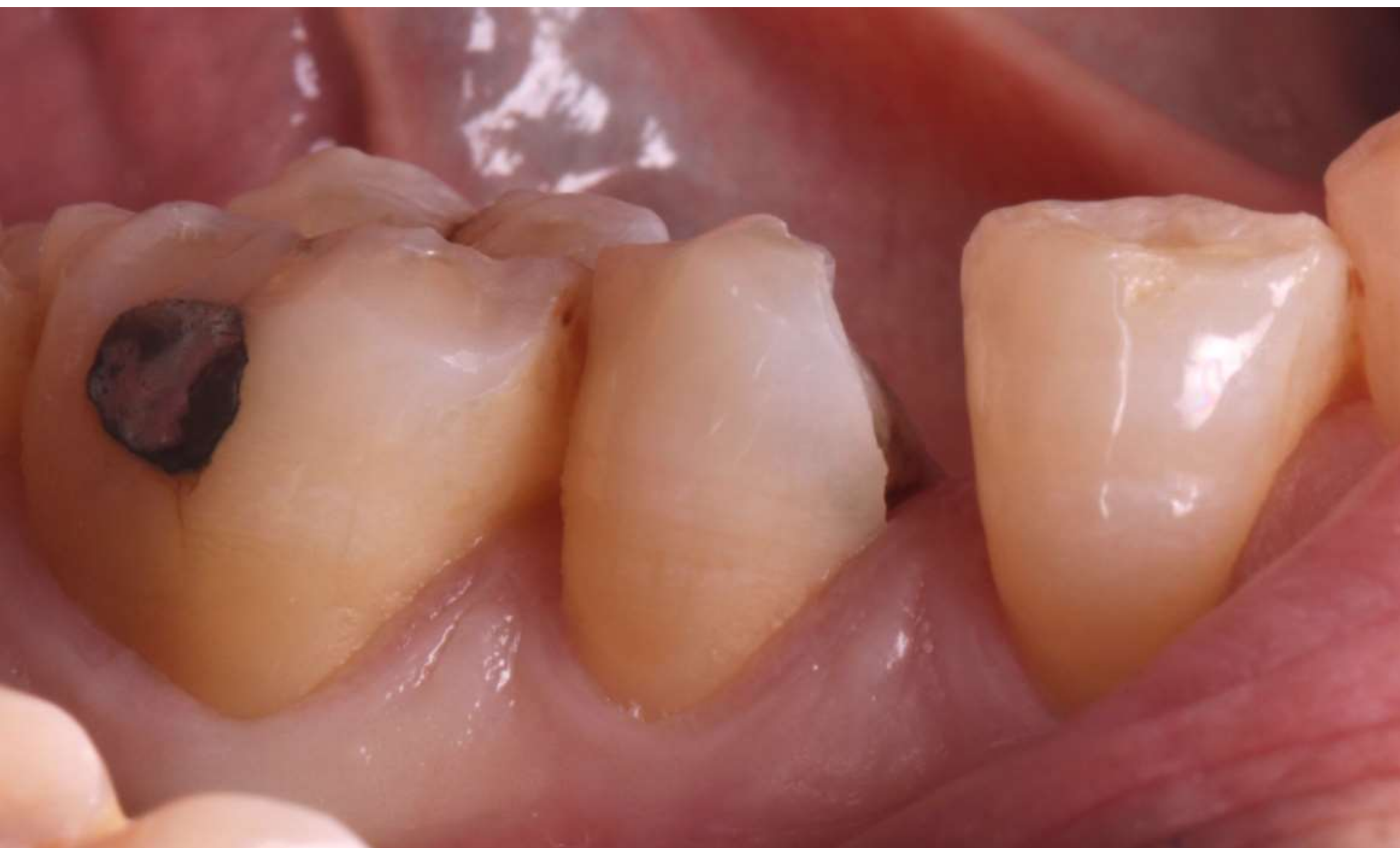


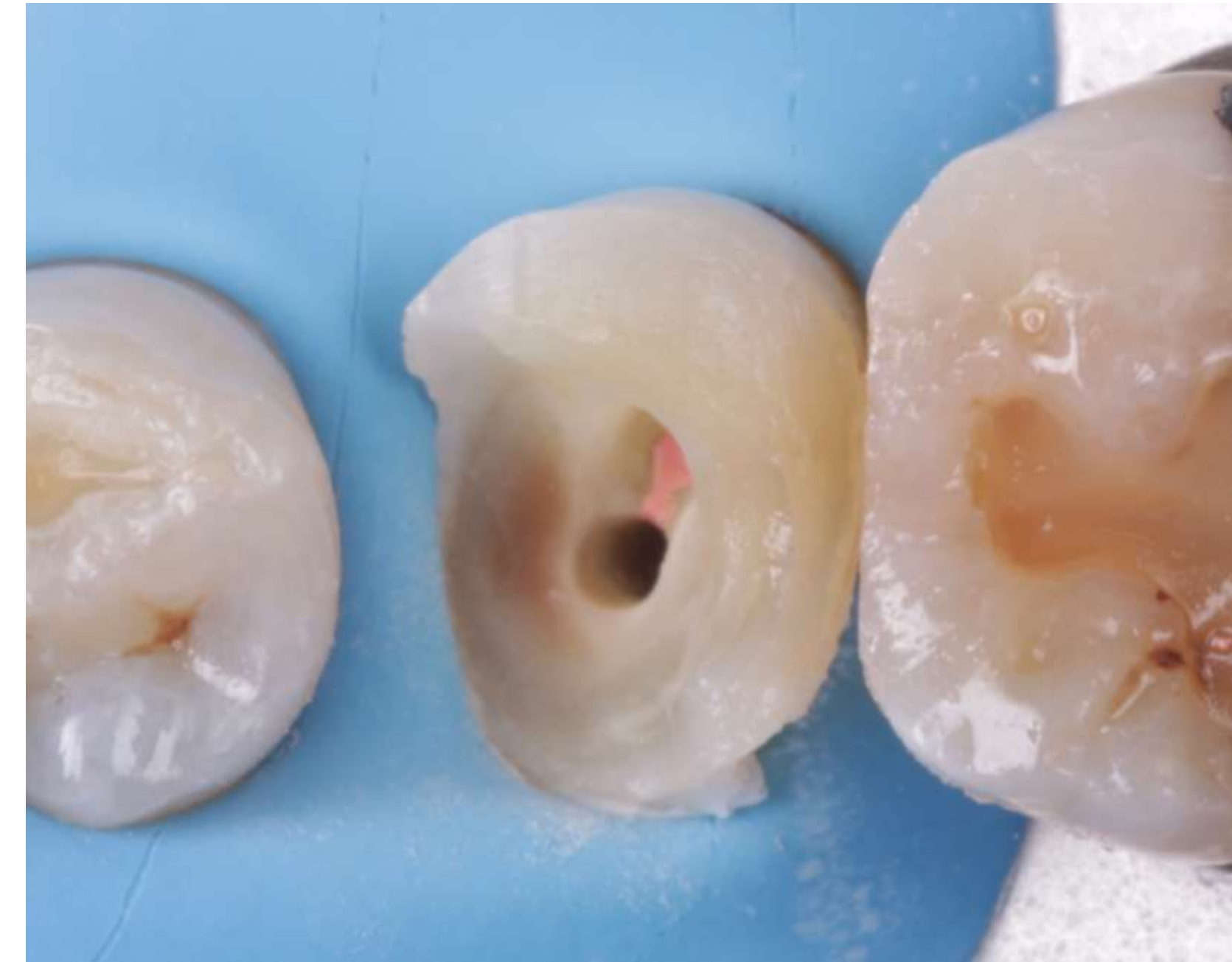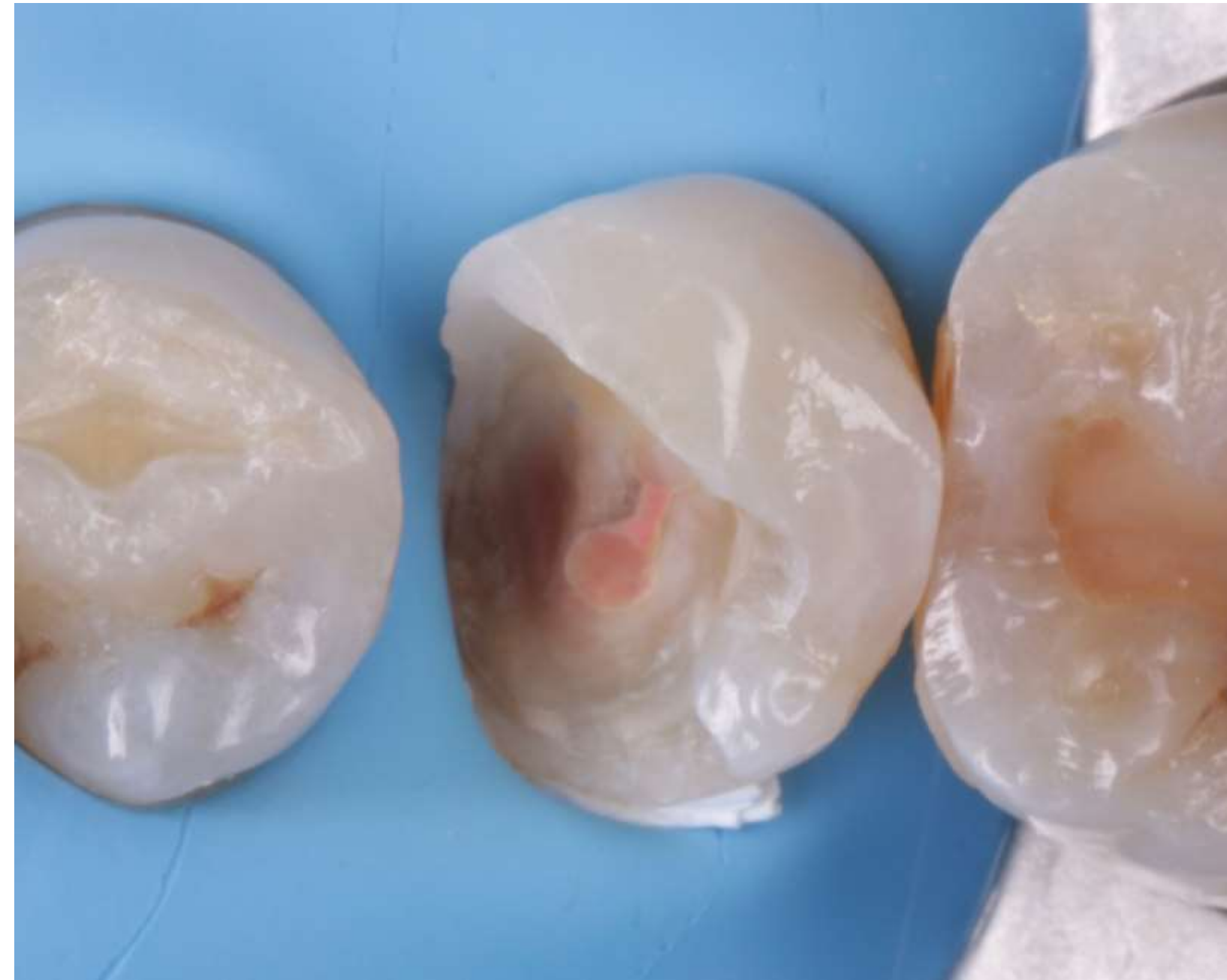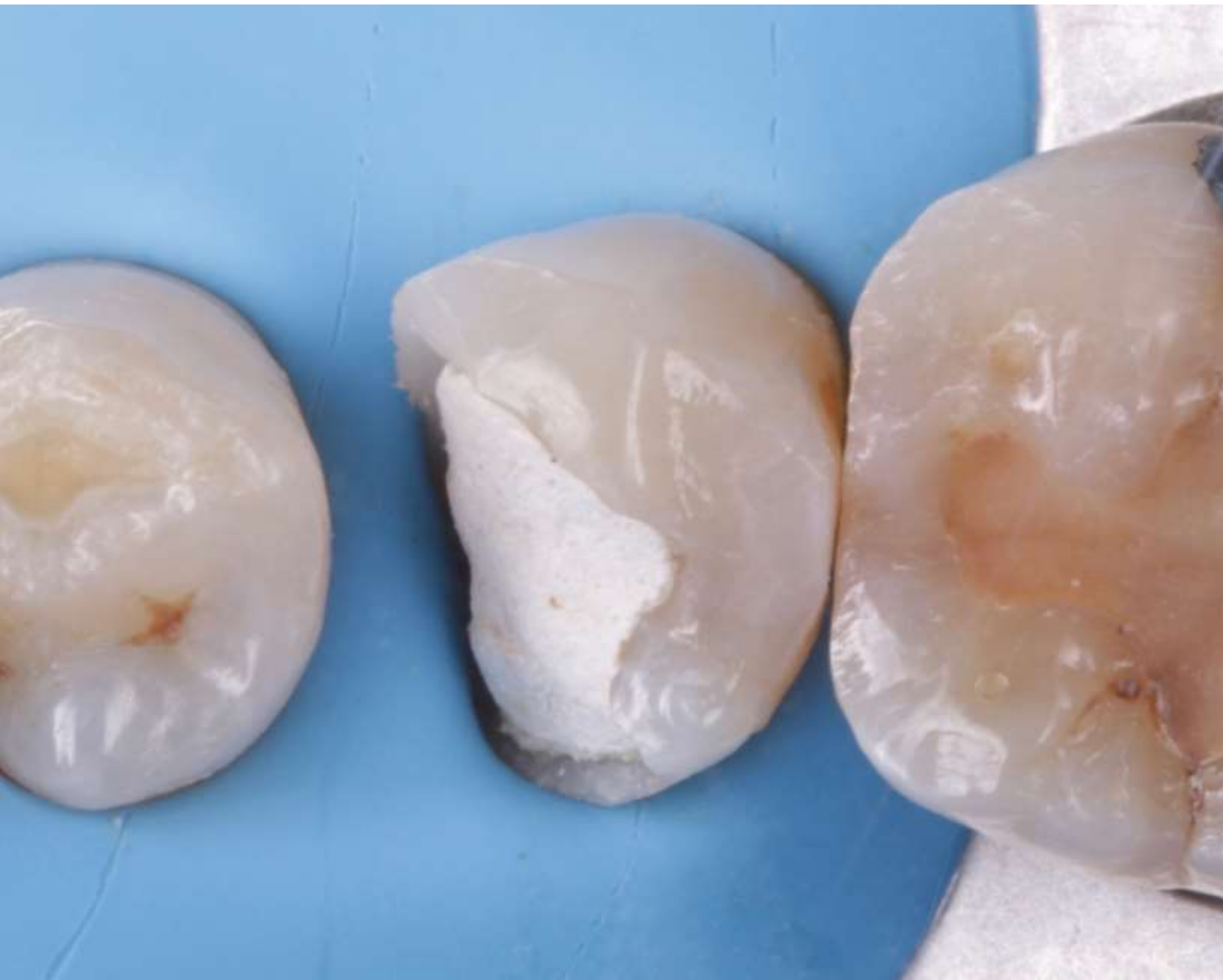Ortopóvoa

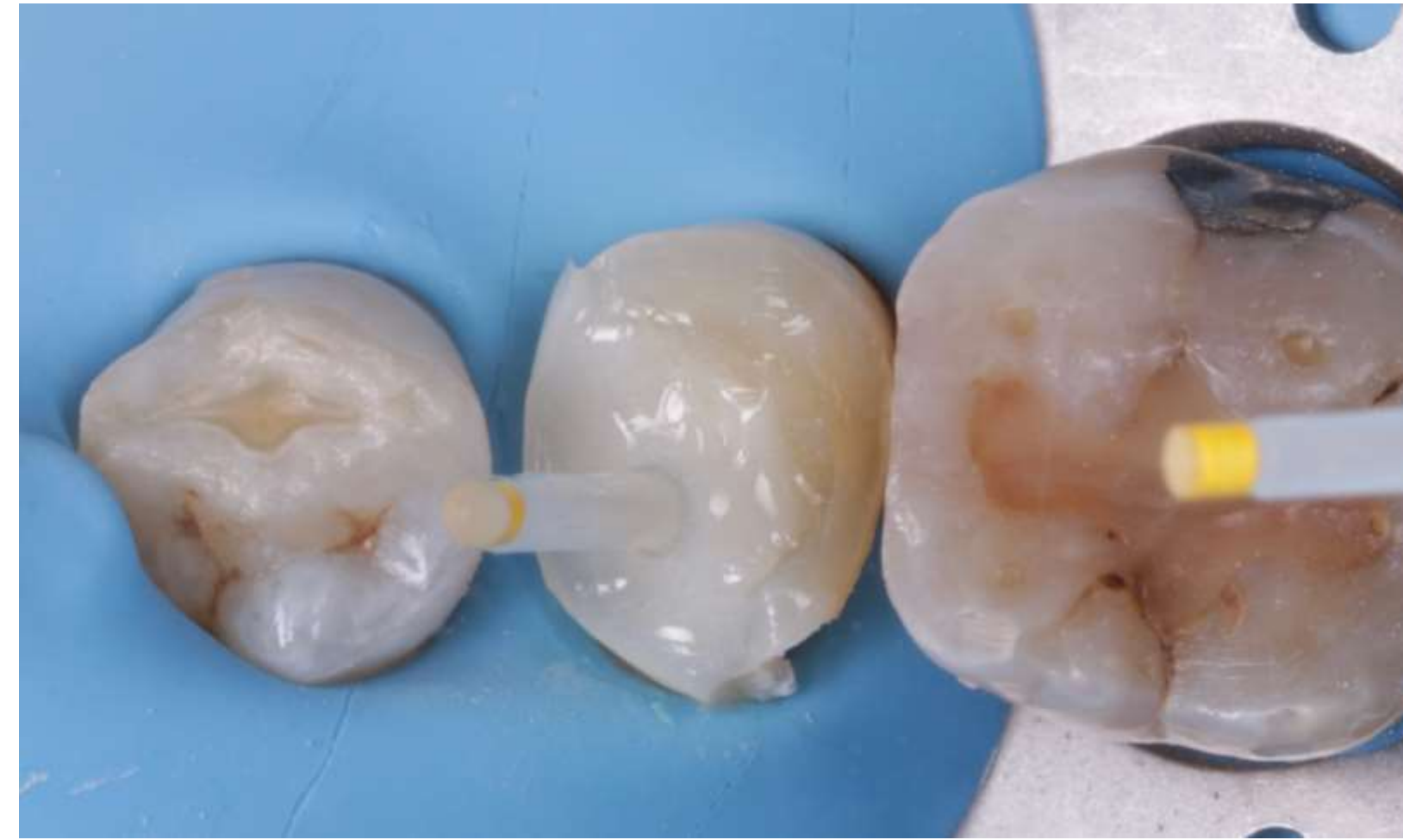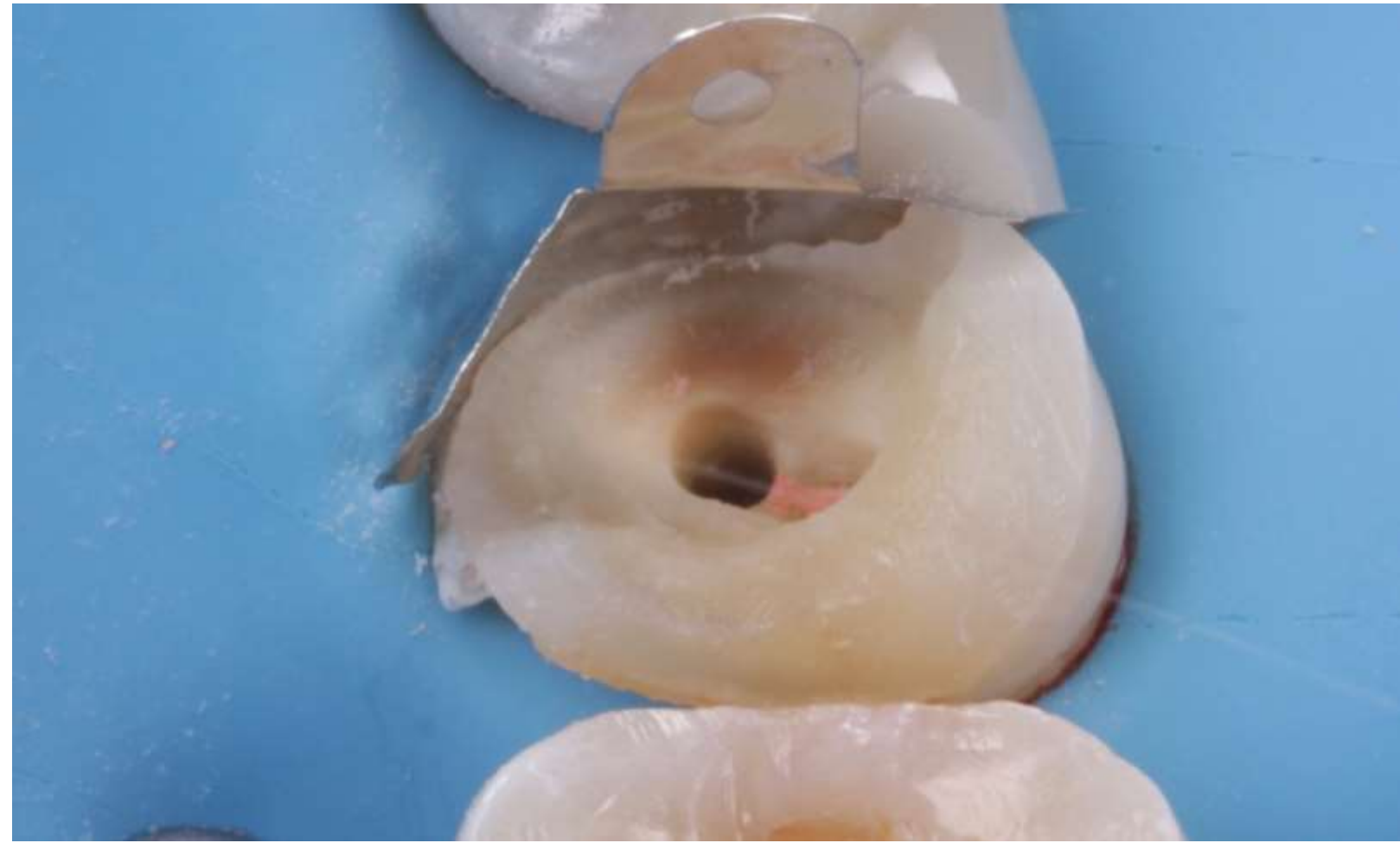
Case of
indirect restoration
(ONLAY)



Initial

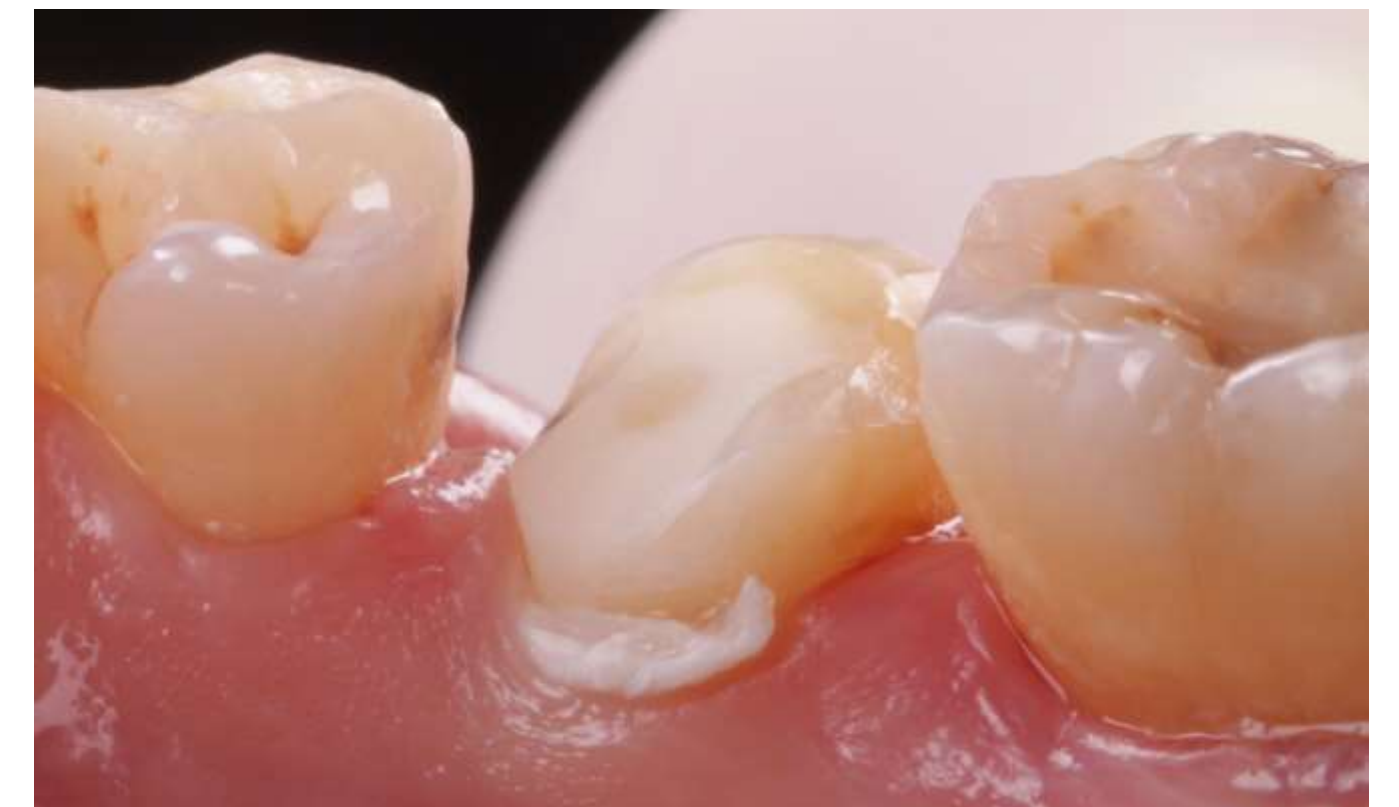
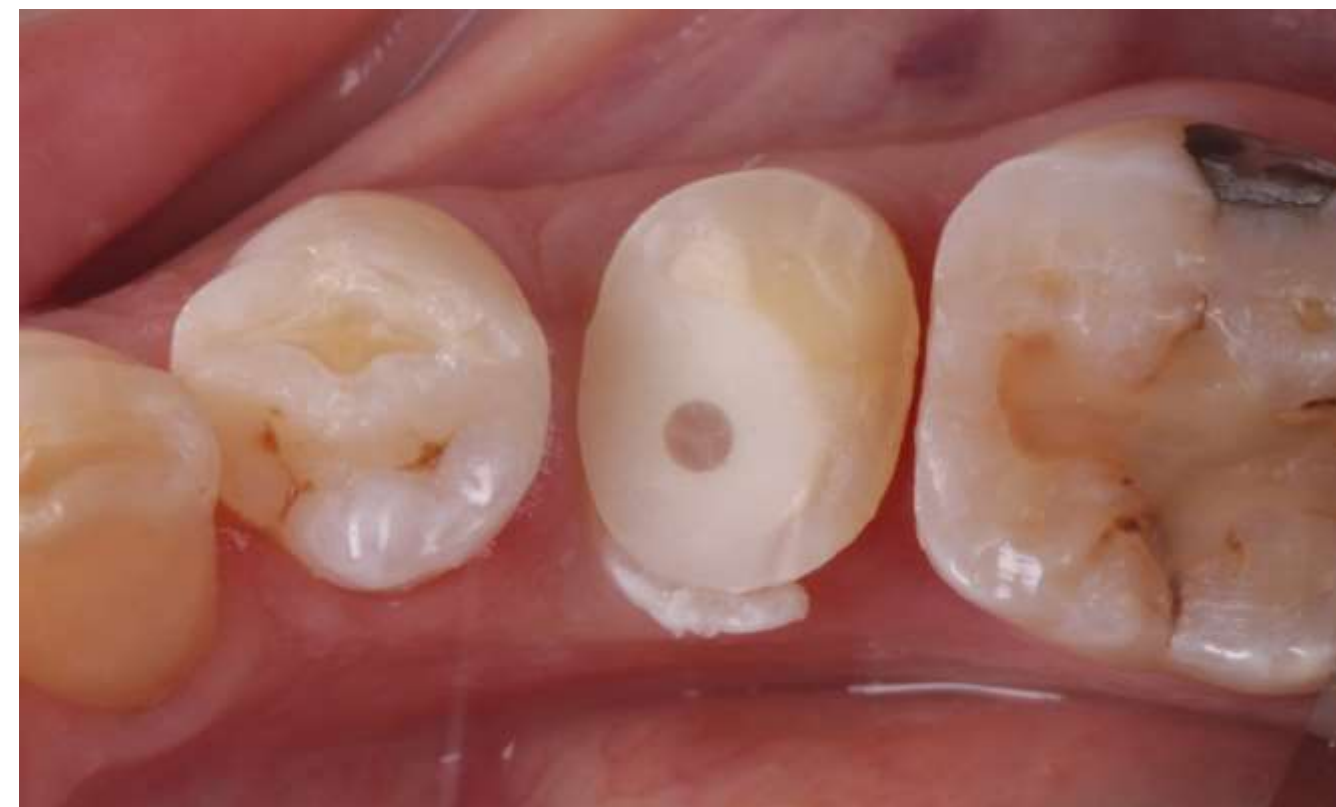
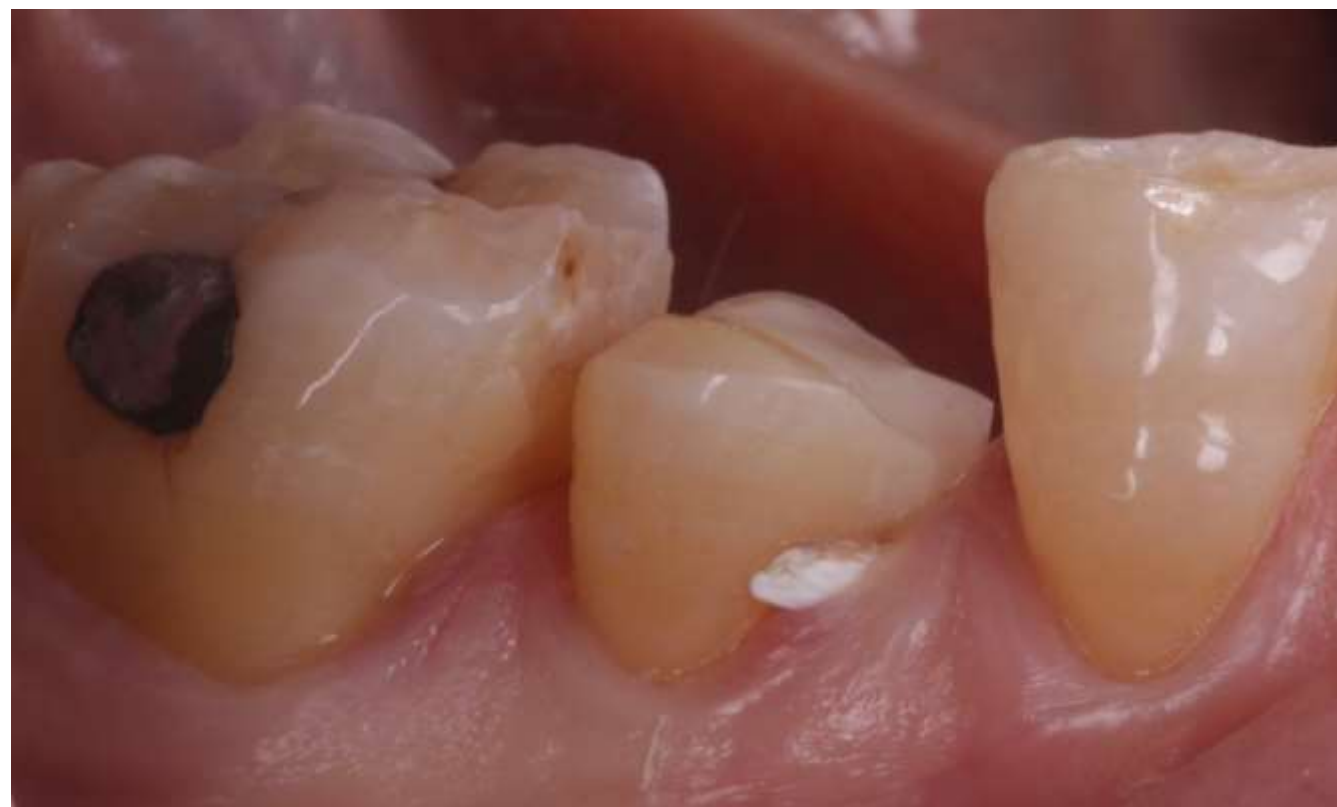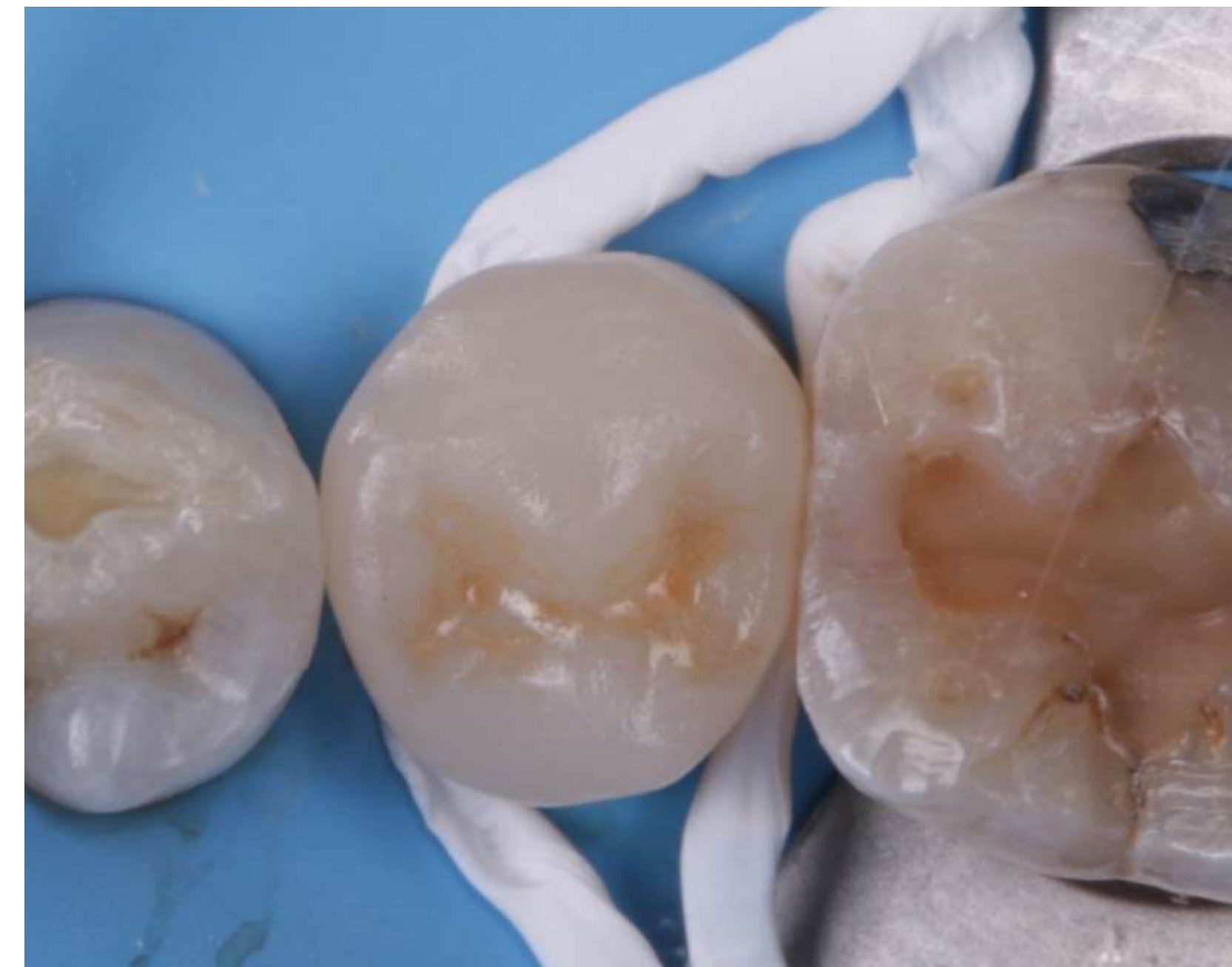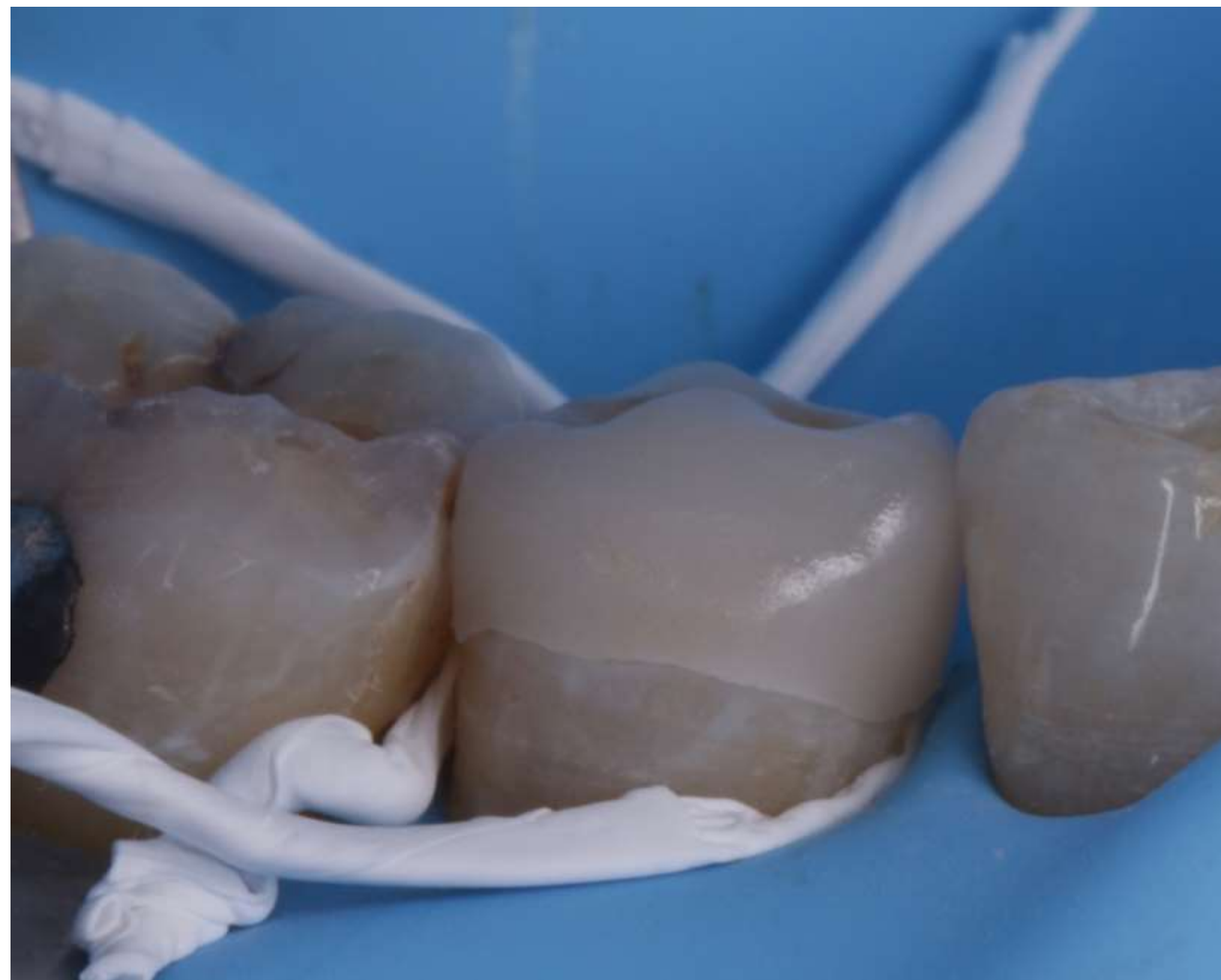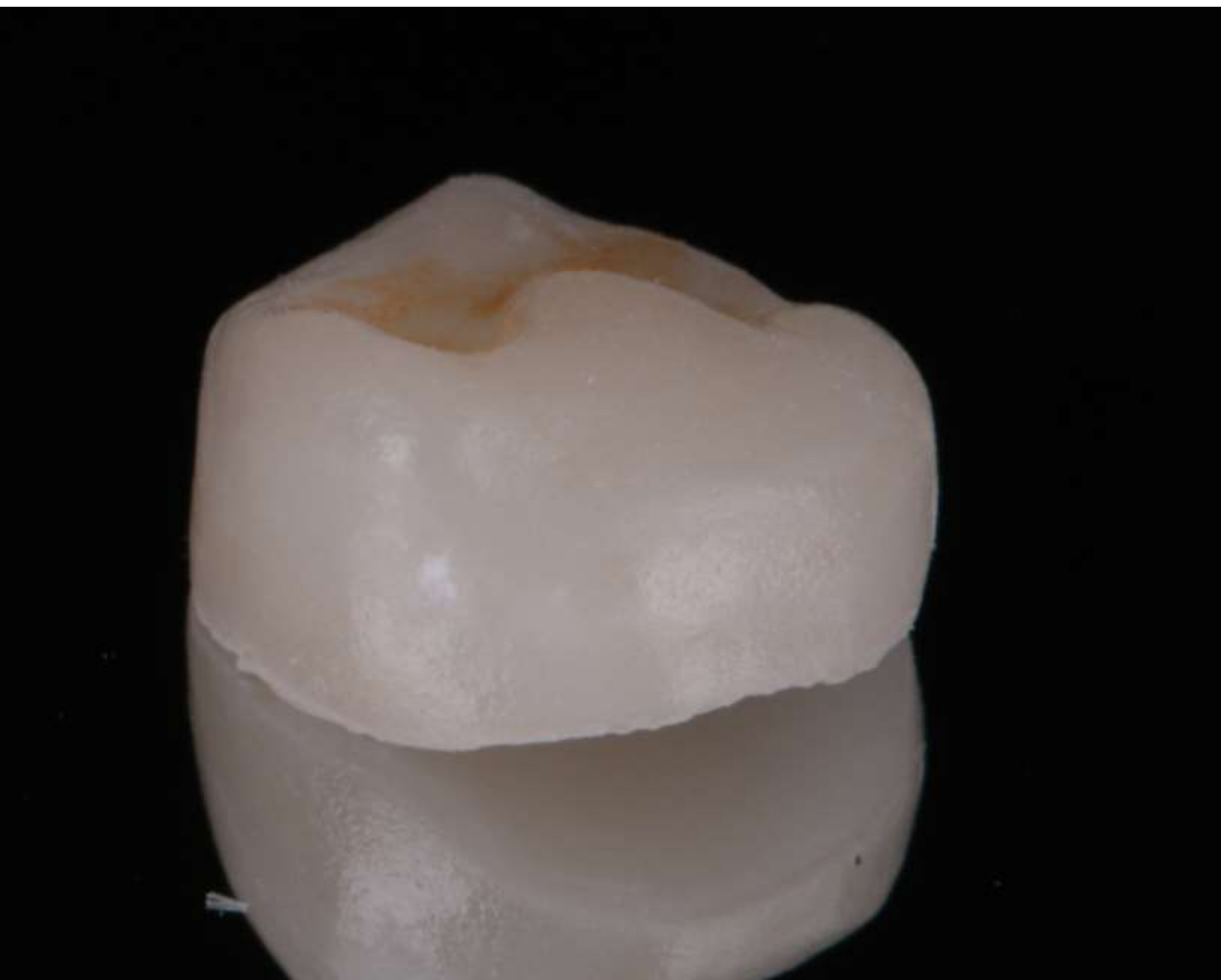Absolute isolation, cleaning and preparation for fiberglass post



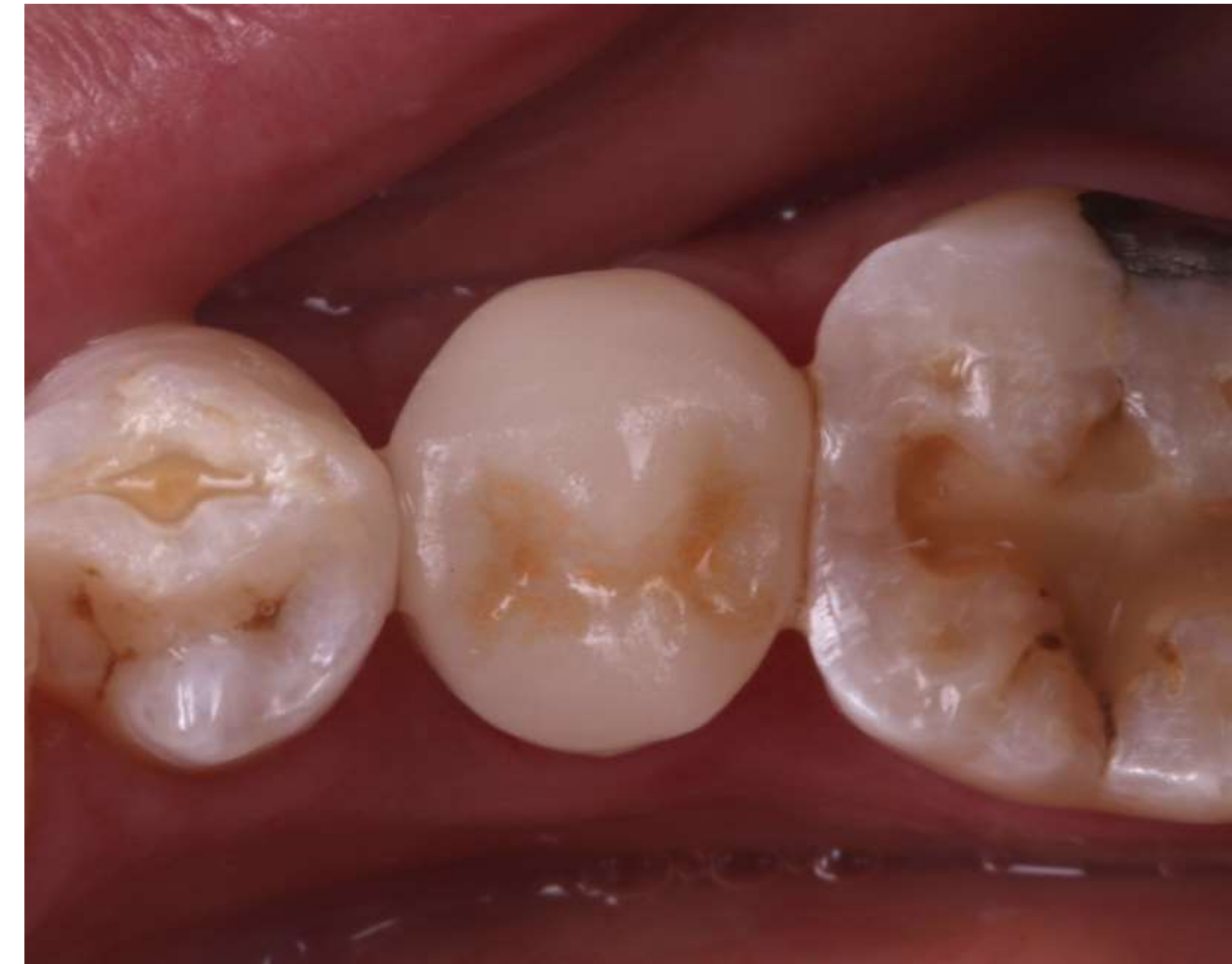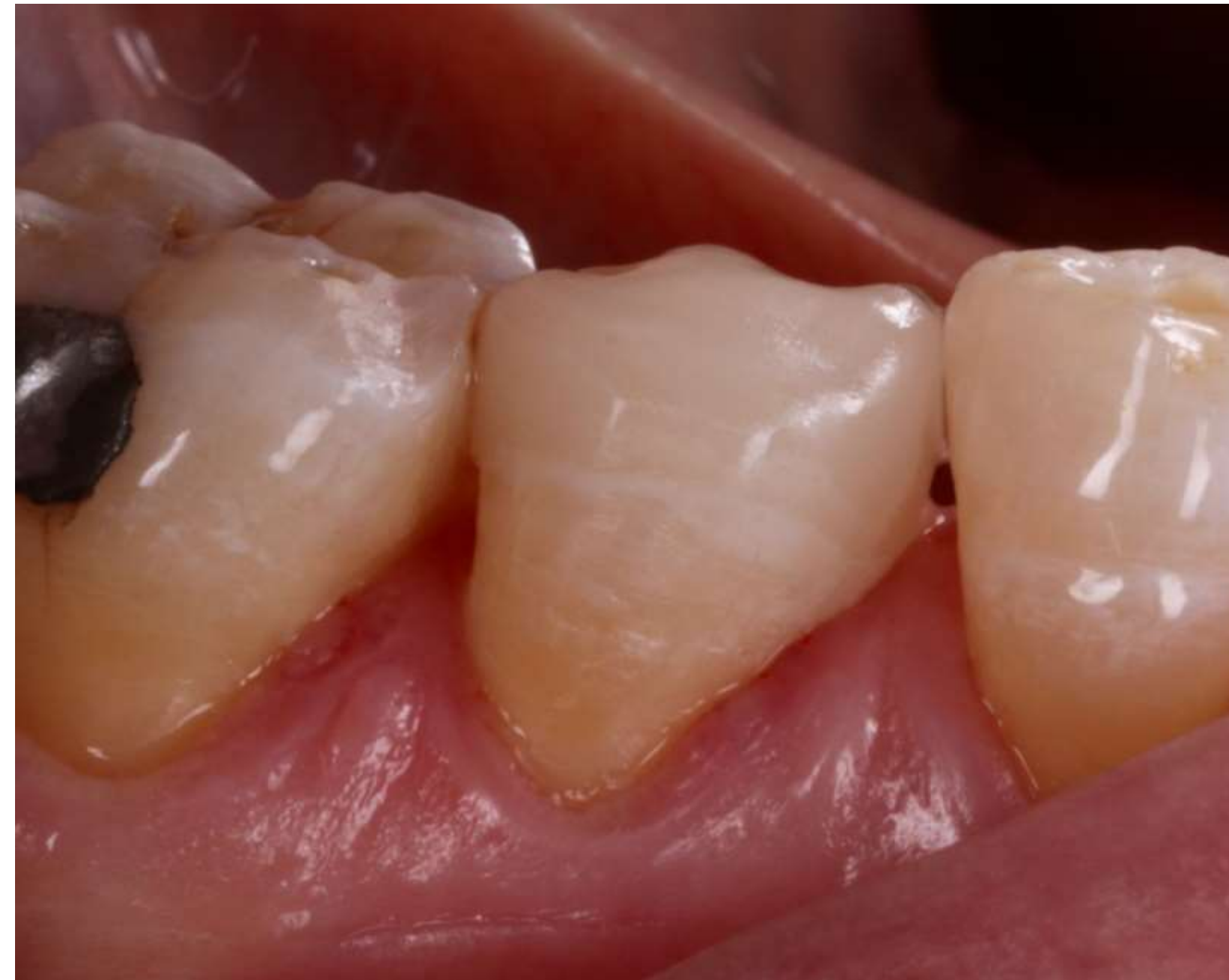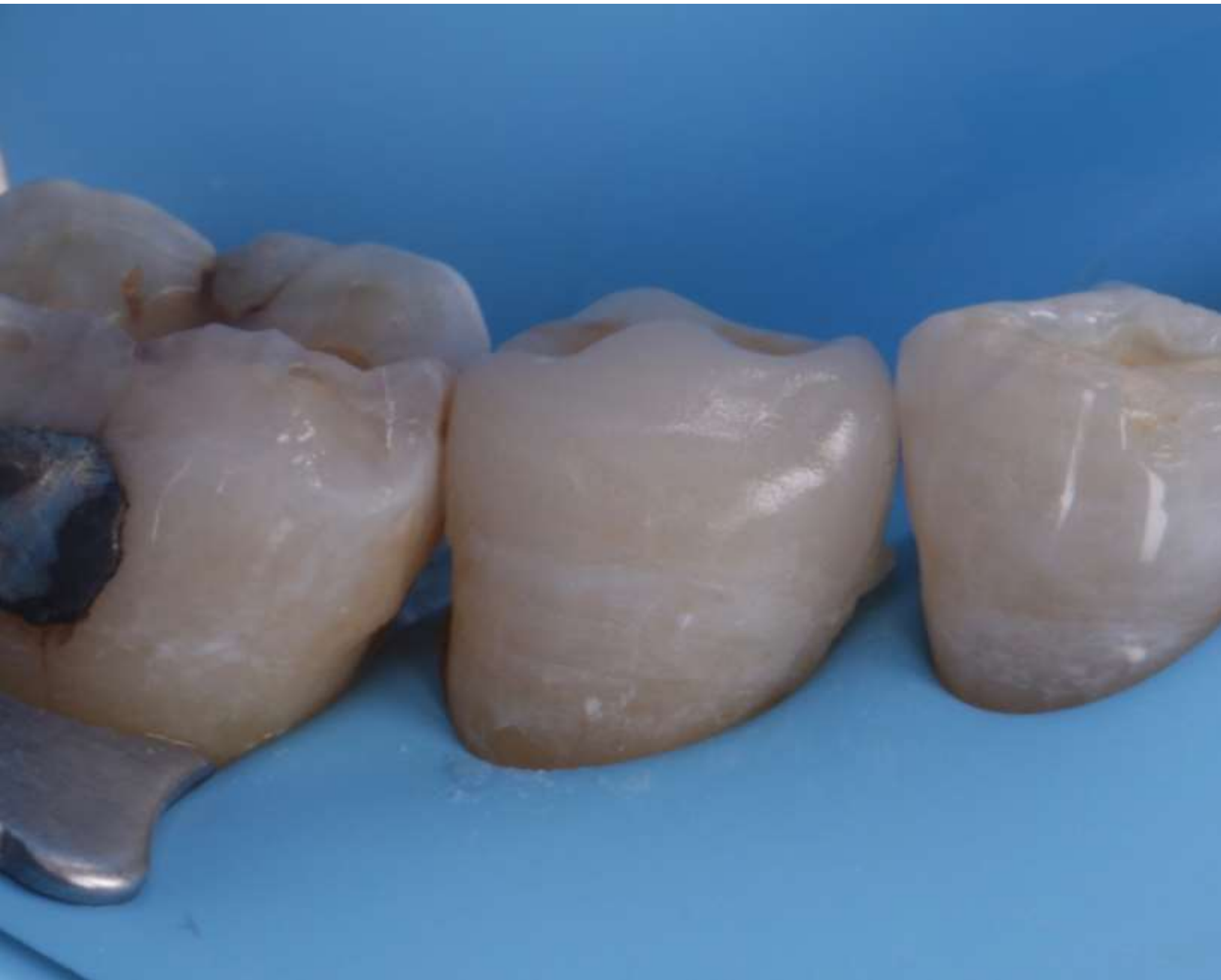Cervical margin elevation and fiberglass post cementation

Preparation complete and ready for intraoral scanner





Proof of ceramic onlay prepared in the same day



Cementing and final result