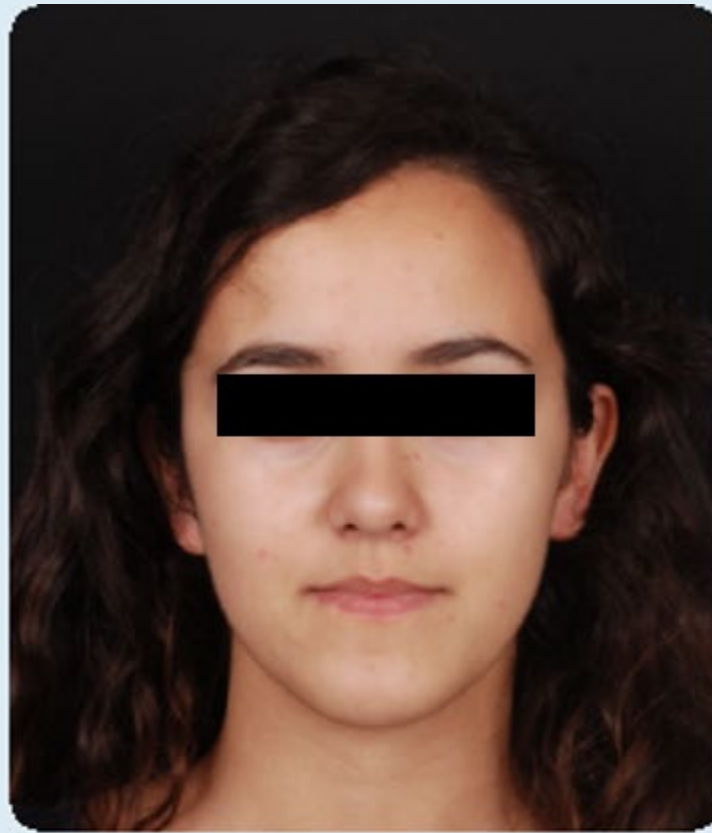
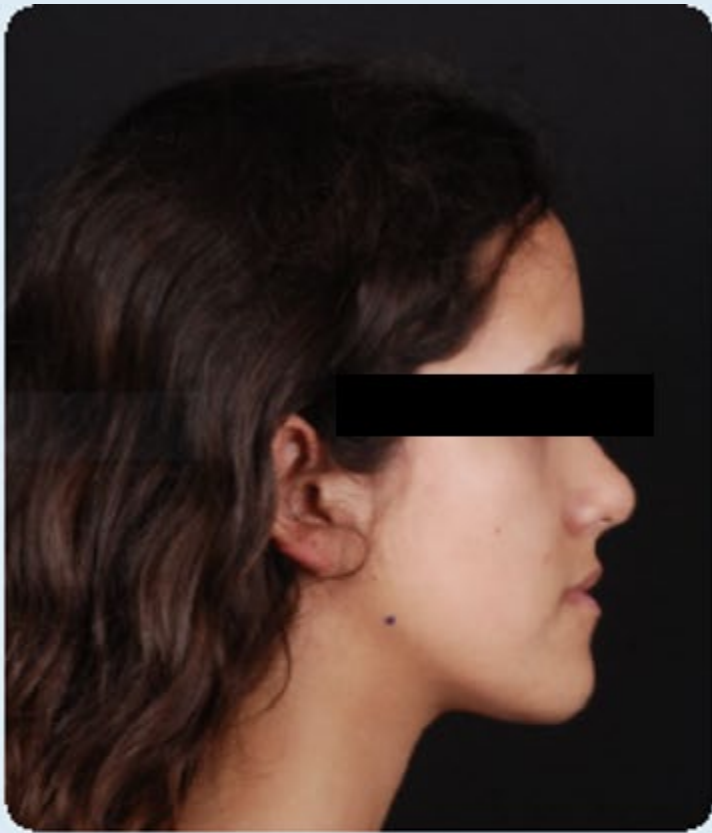


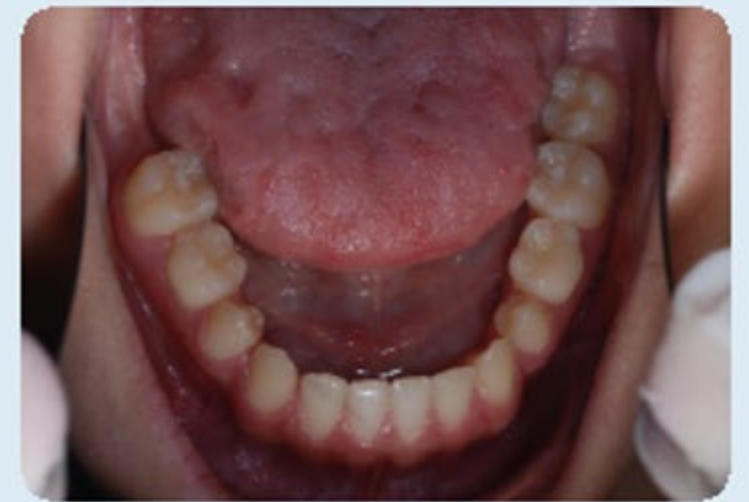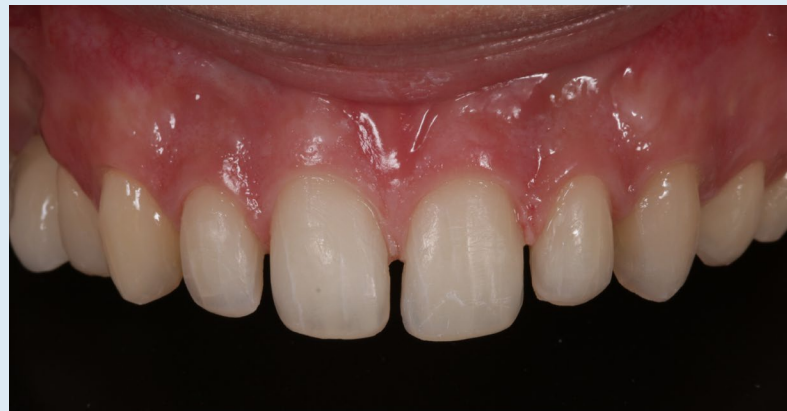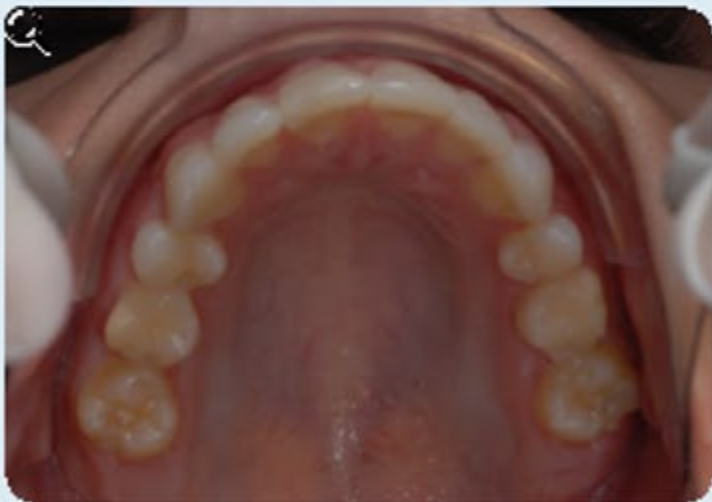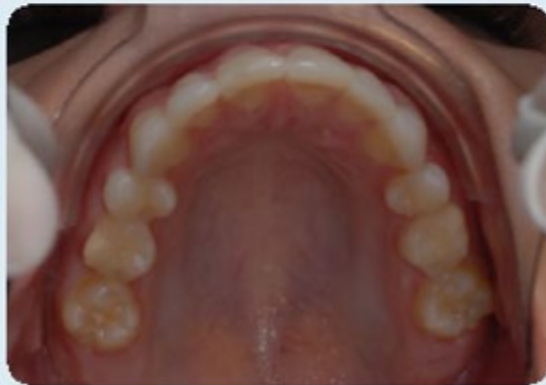
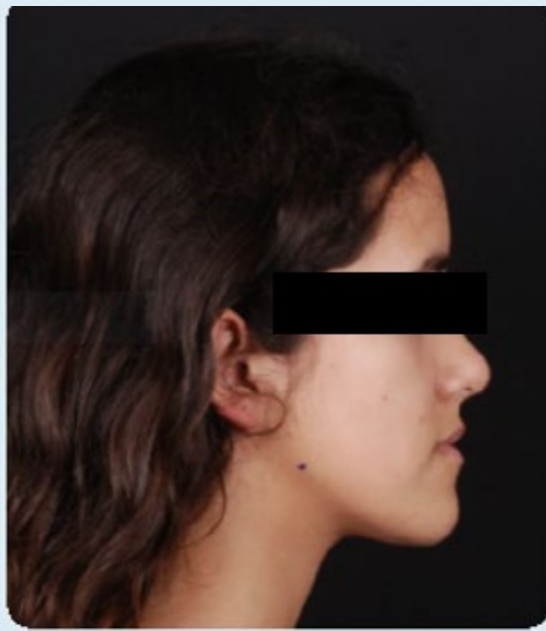Ortopóvoa

Complex
interdisciplinary
cases



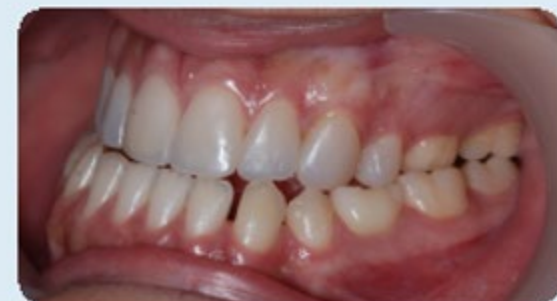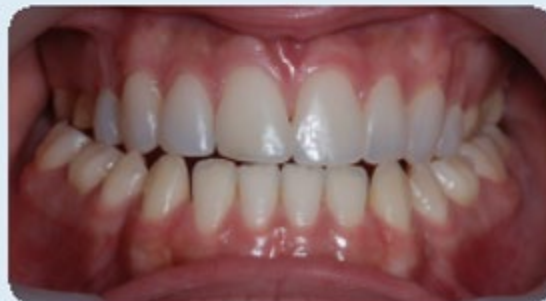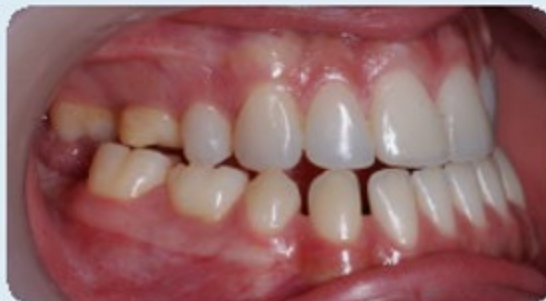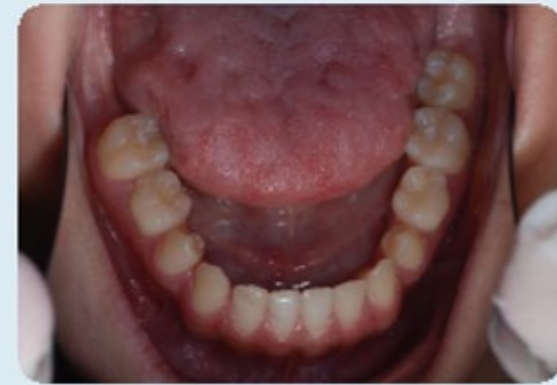**Complex interdisciplinary case
INITIAL**





Complex interdisciplinary case

After coronary augmentation
of upper incisors
with composite

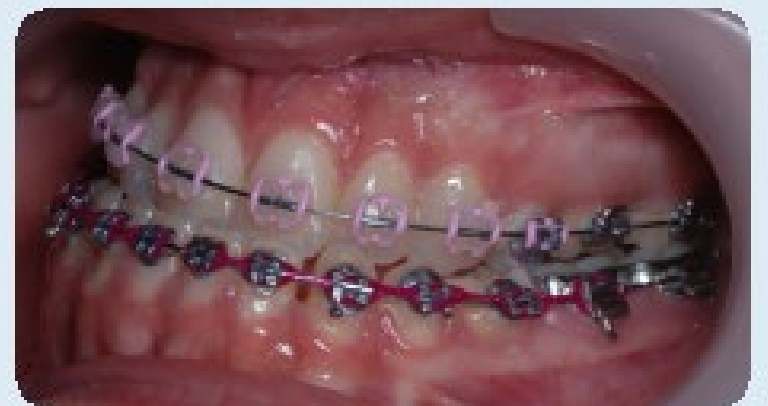
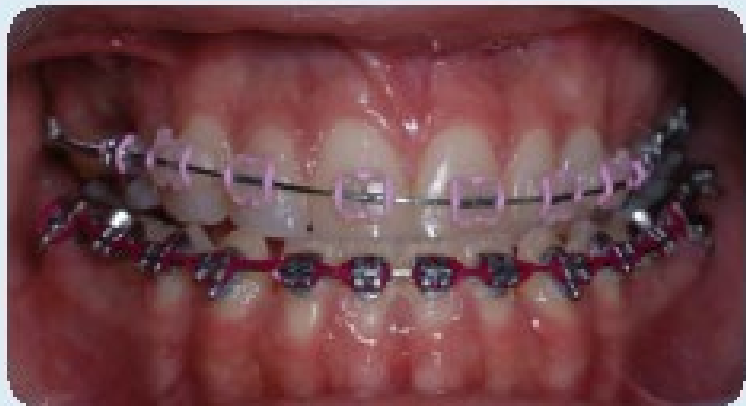
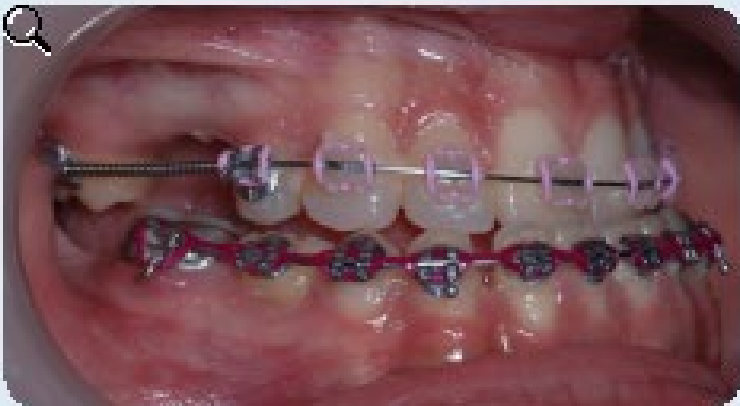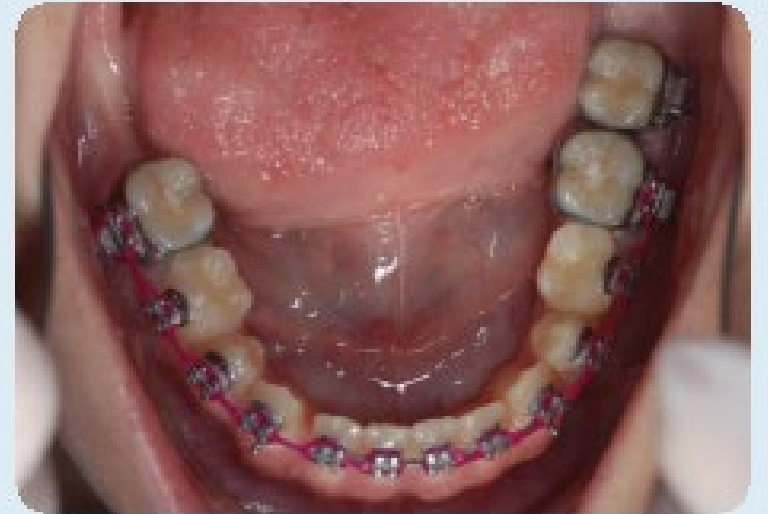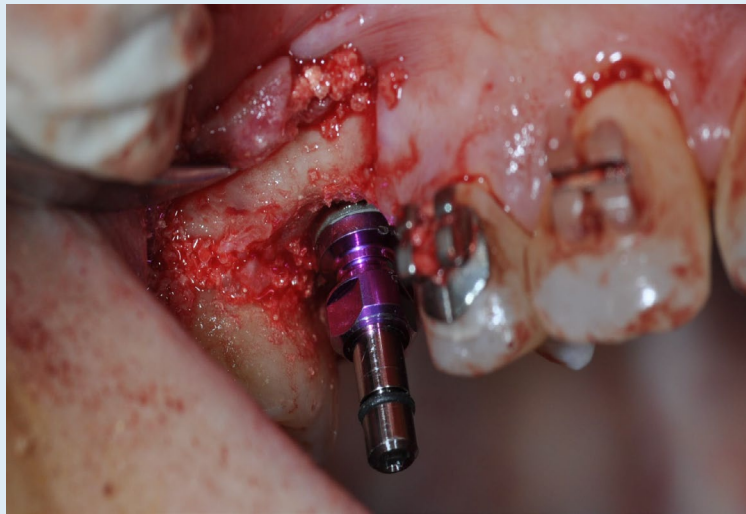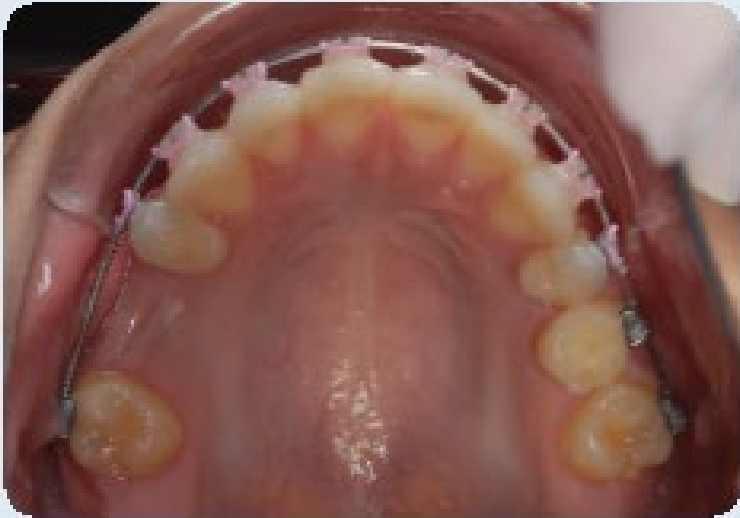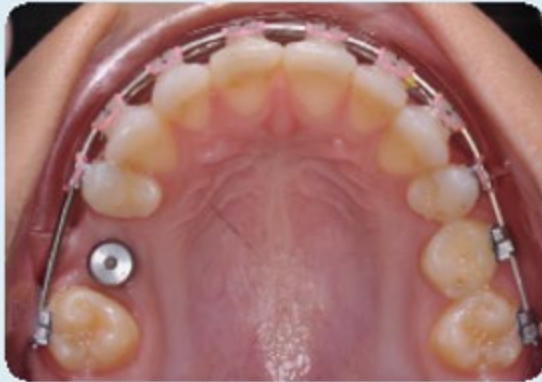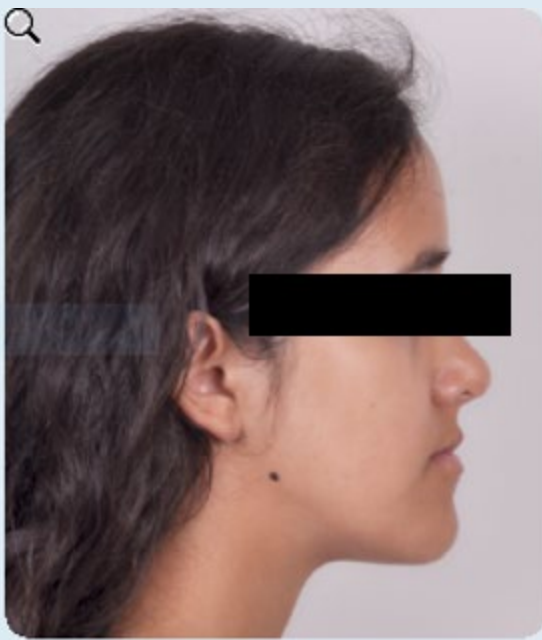Complex interdisciplinary case

Progress

Orthodontic treatment

Placement of implant

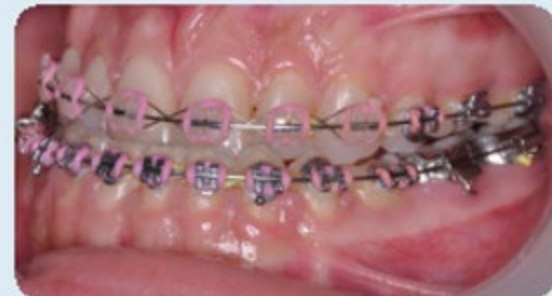
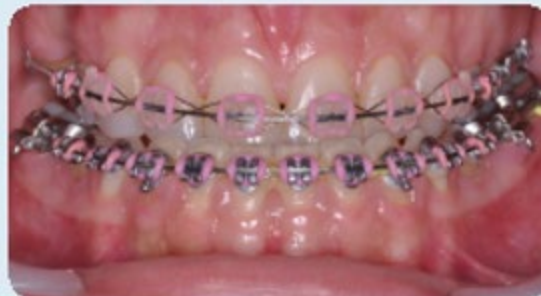
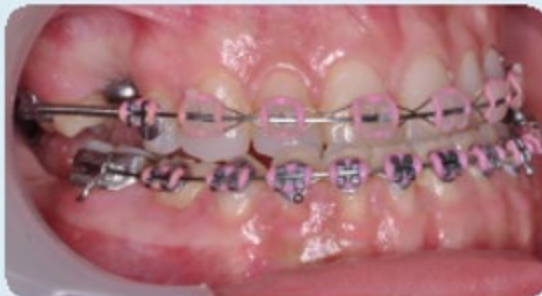
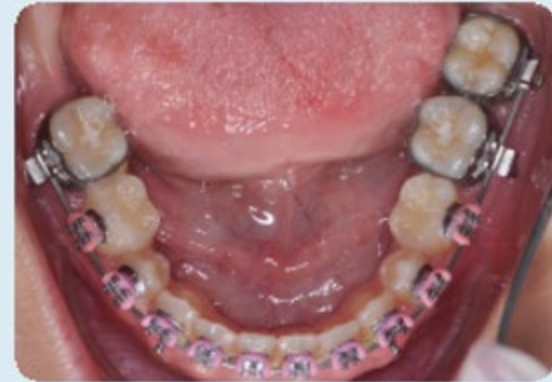
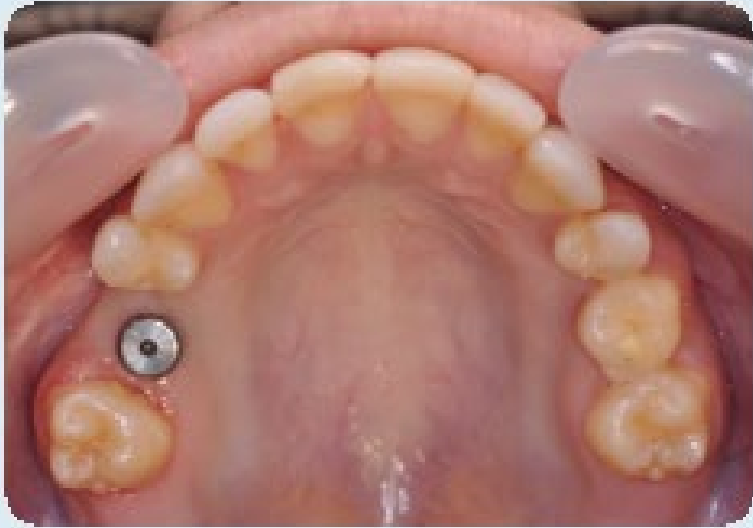Complex interdisciplinary case

Progress

**Preparation for
orthognathic surgery
Upper jaw advancement**

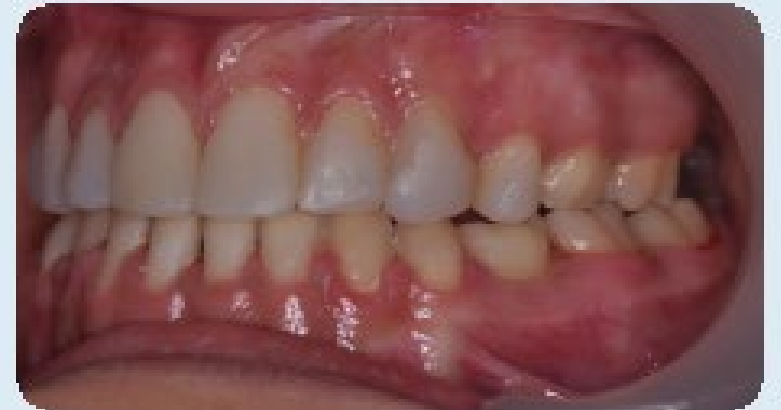
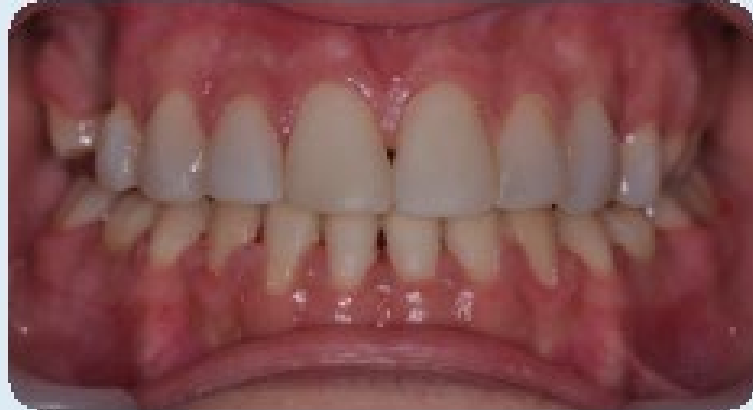
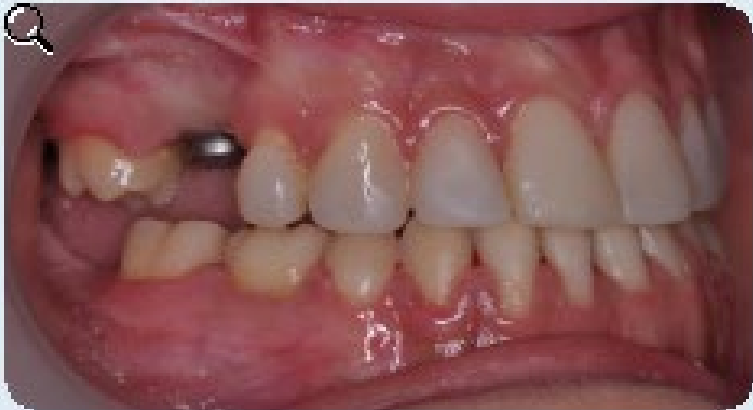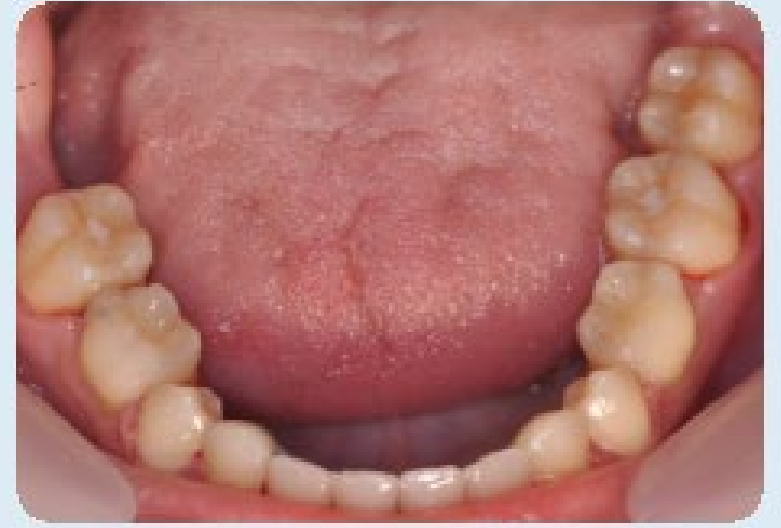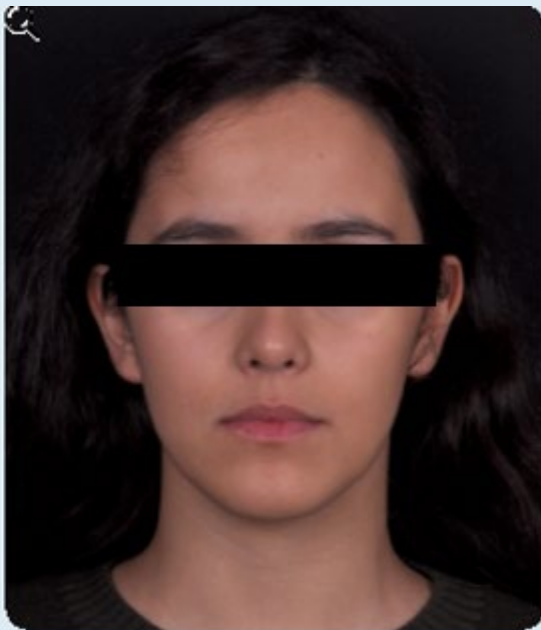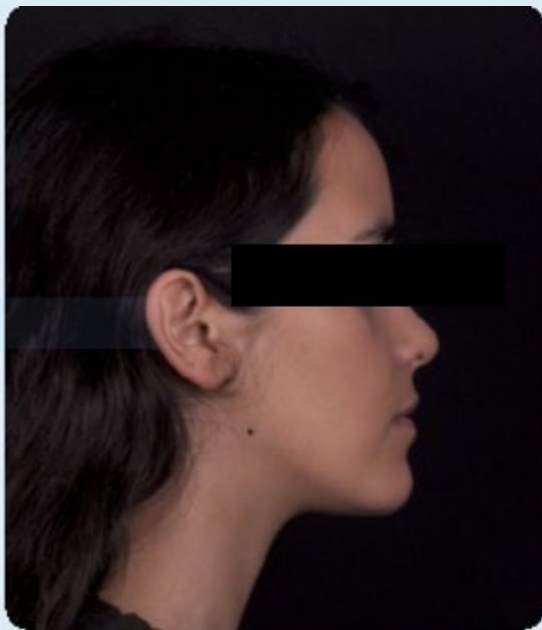


Complex interdisciplinary case

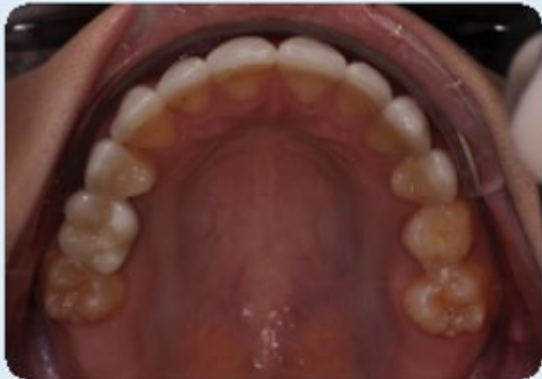Progress

**After orthodontic-surgical treatment
and placement of implant**

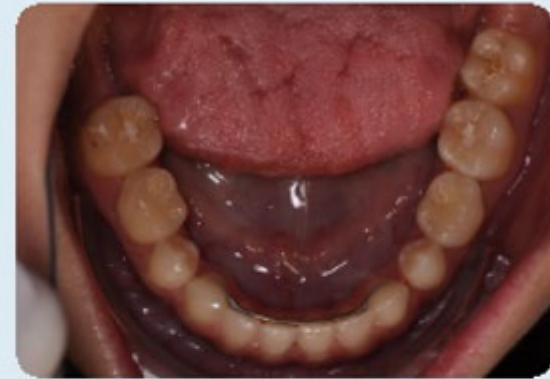



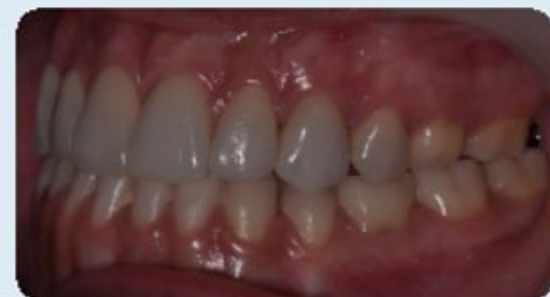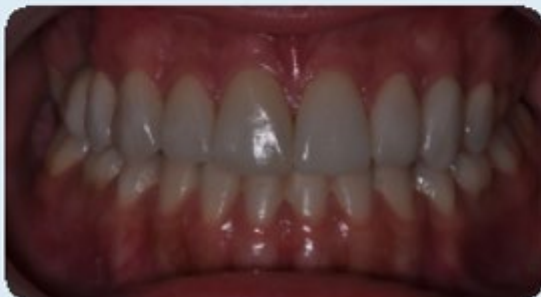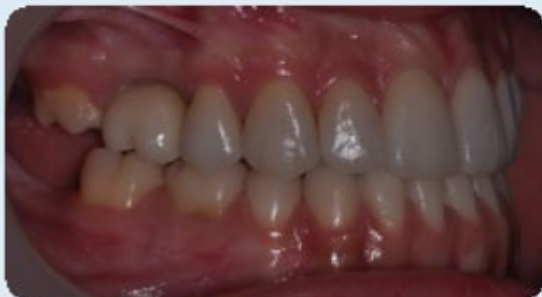Complex interdisciplinary case

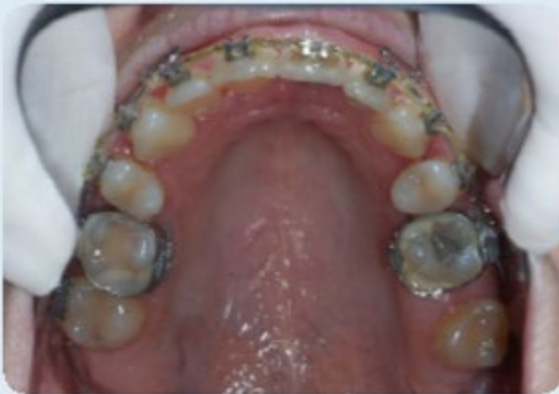
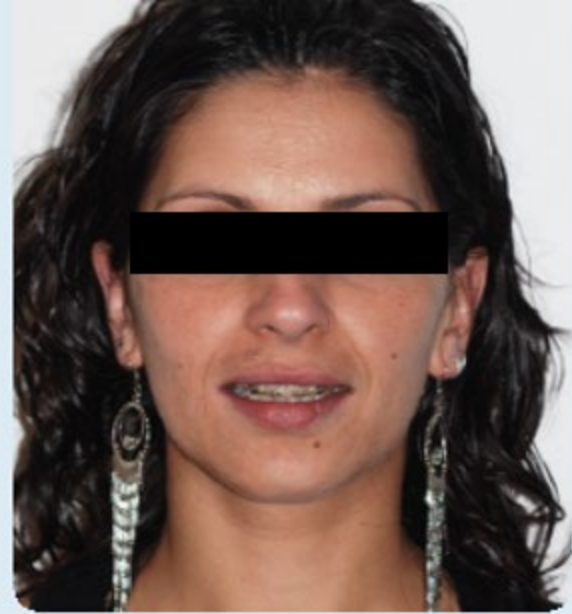
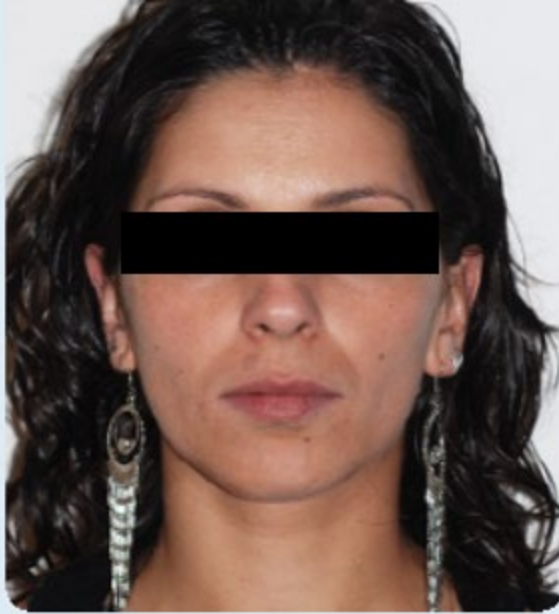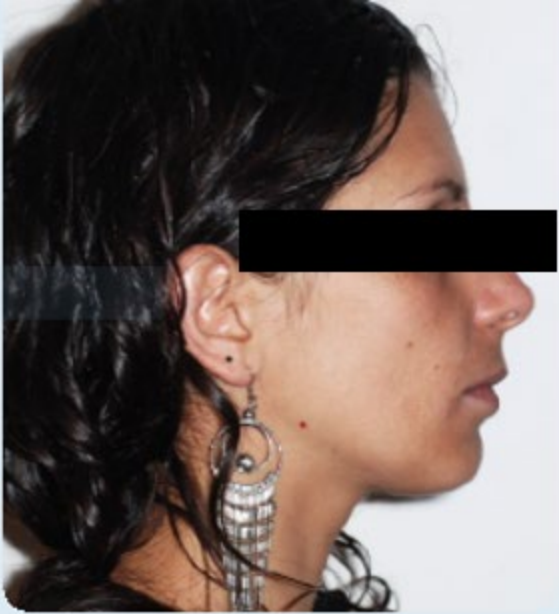**After orthodontic-surgical treatment,
placement of implant-supported
tooth and ceramic veneers
in the upper incisors**



FINAL

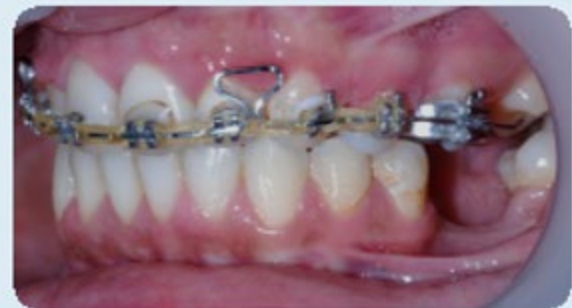
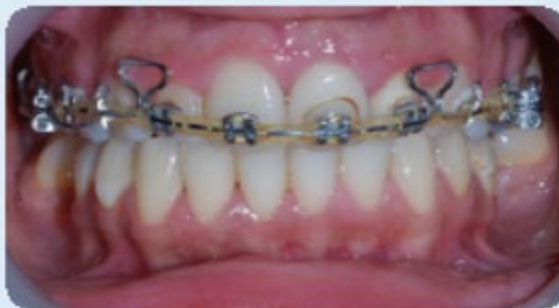
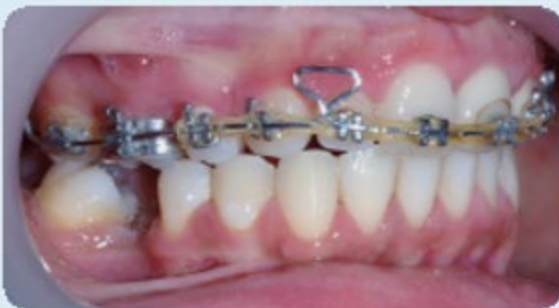
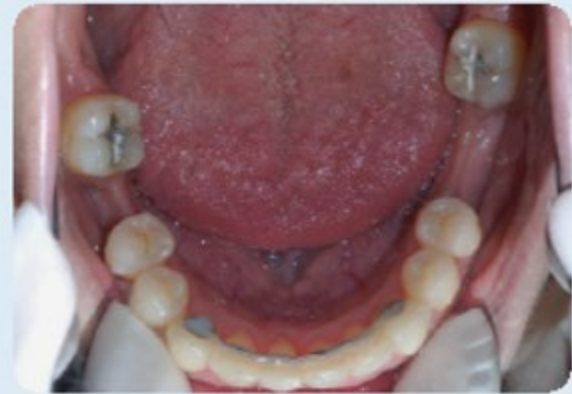
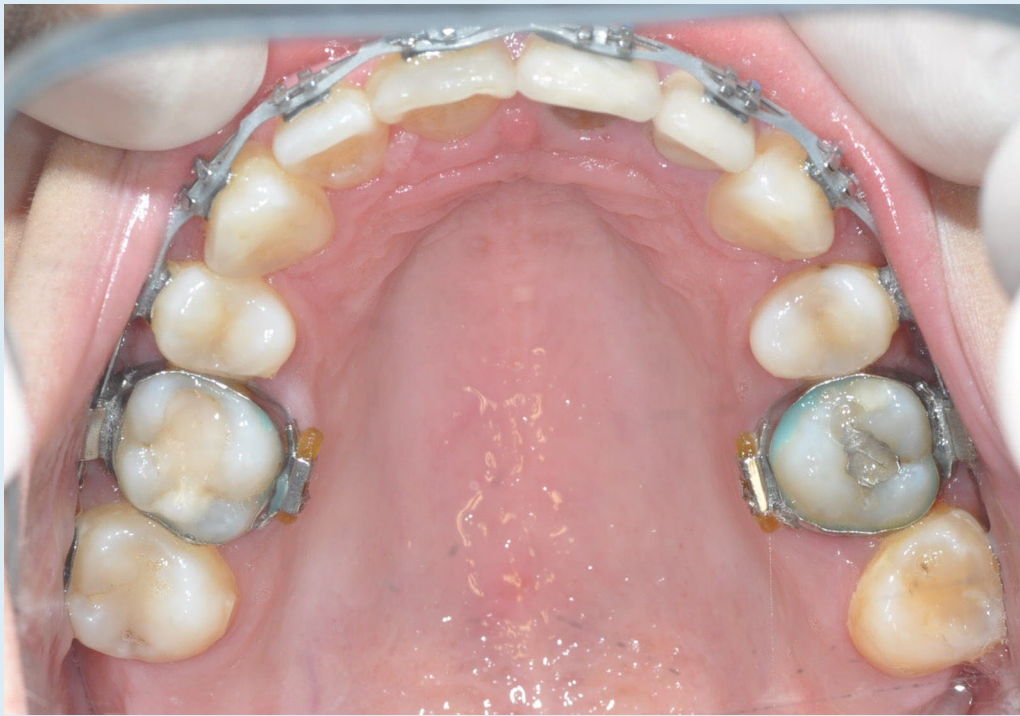Complex interdisciplinary case

INITIAL

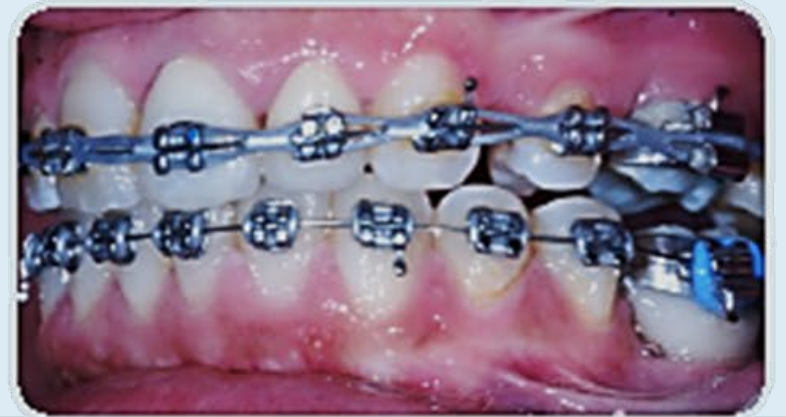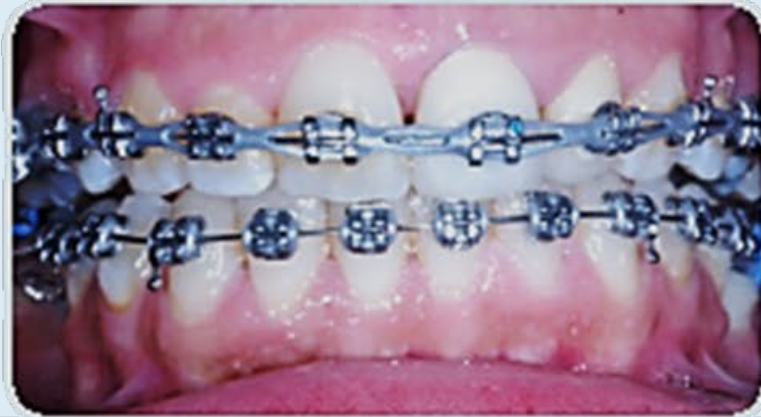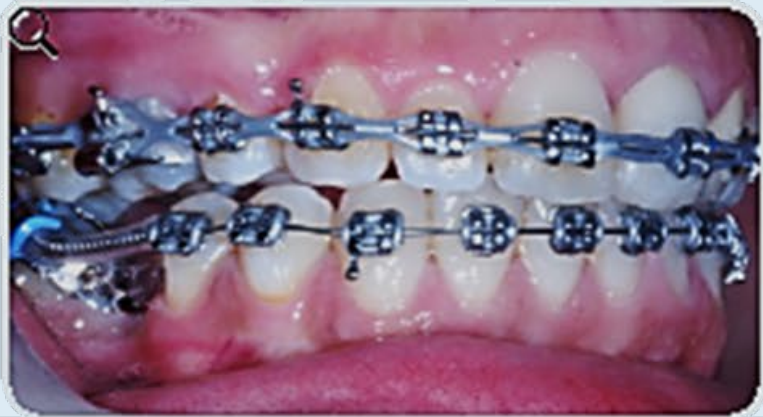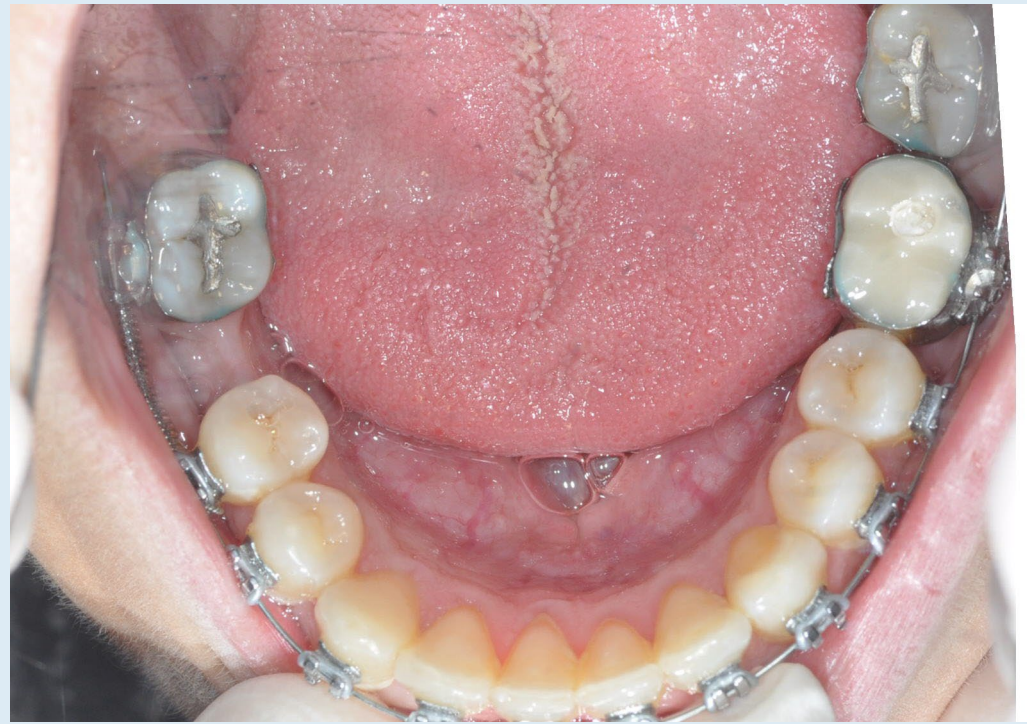(case with 3 years of bad treatment)

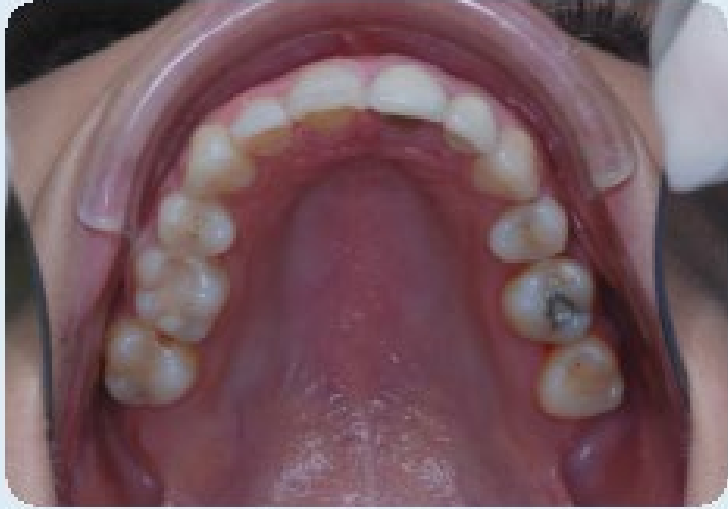



**Complex
interdisciplinary
case**

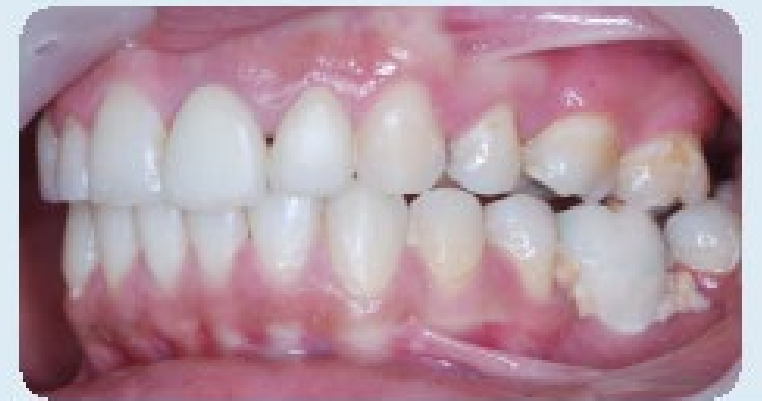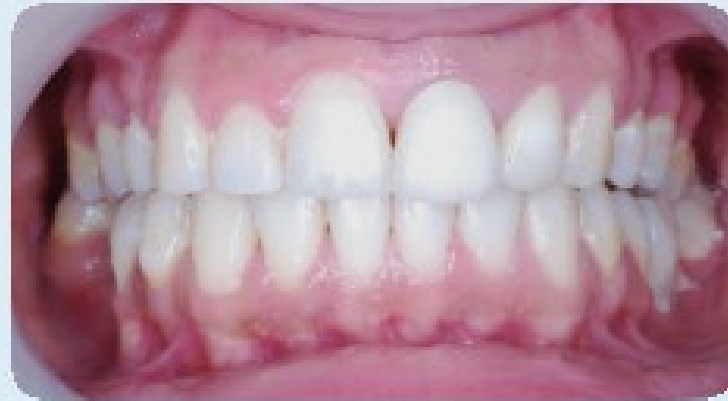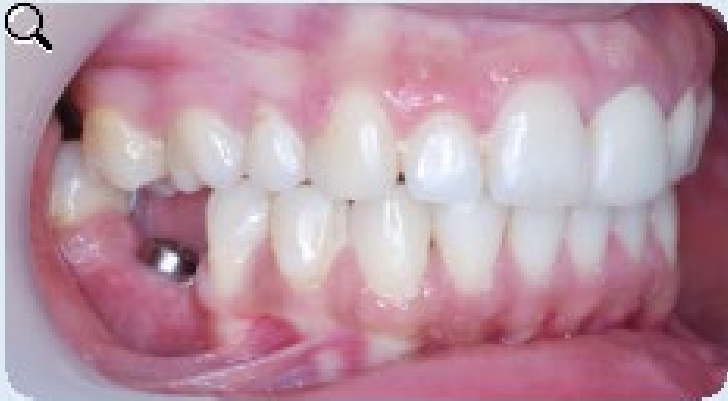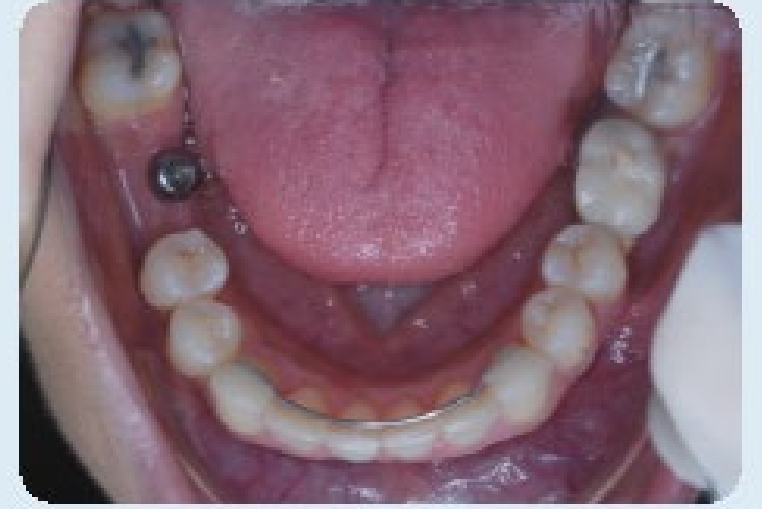PROGRESS

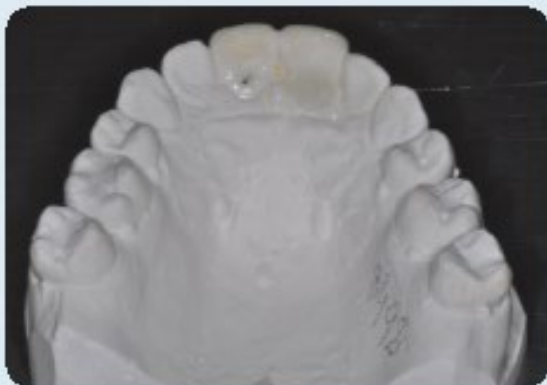
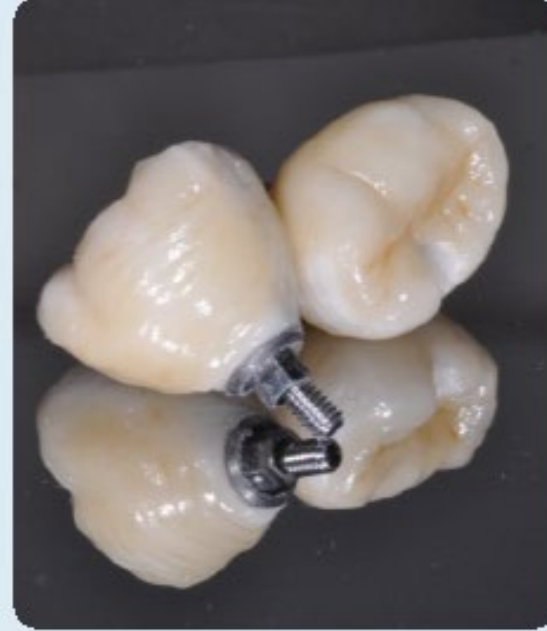
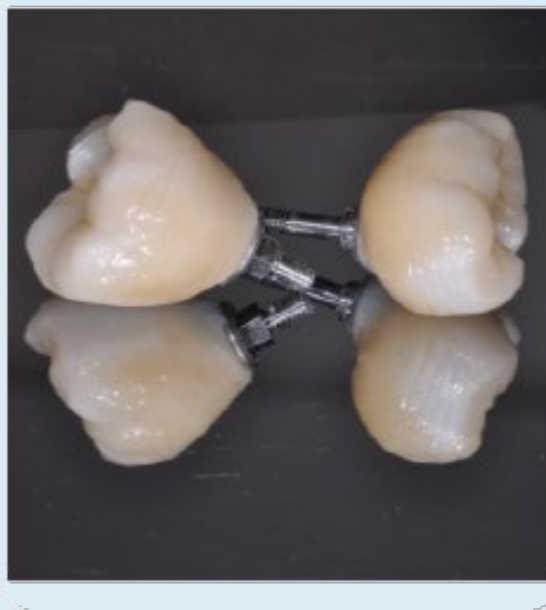
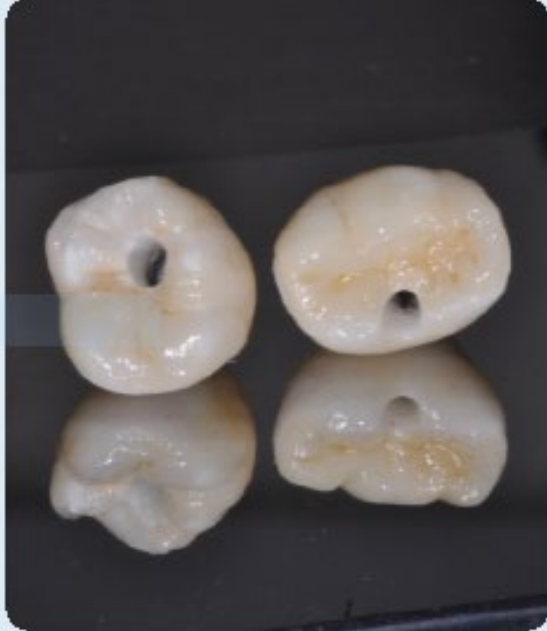
Complex interdisciplinary treatment

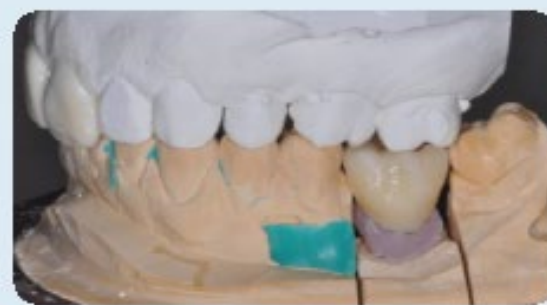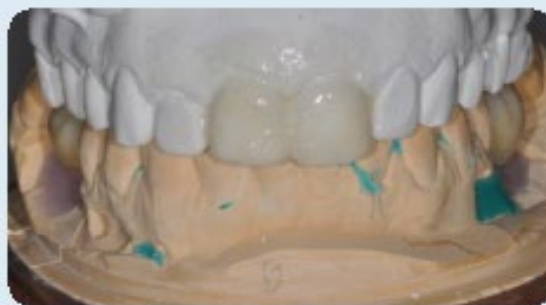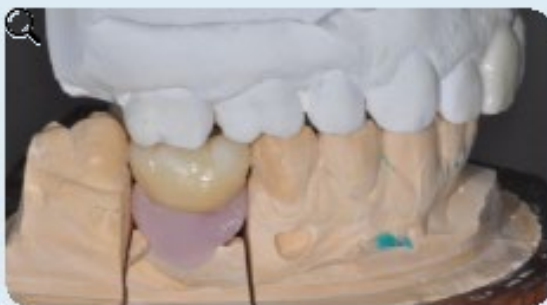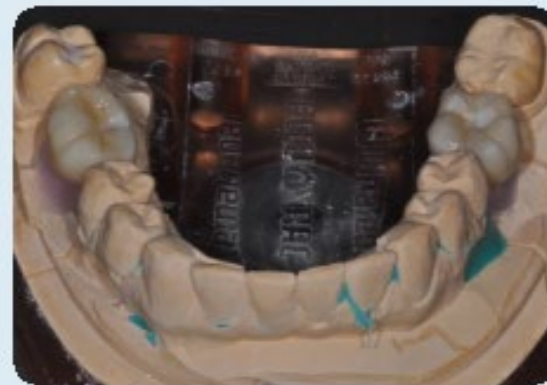
**End of the orthodontic treatment
and placement of implants**

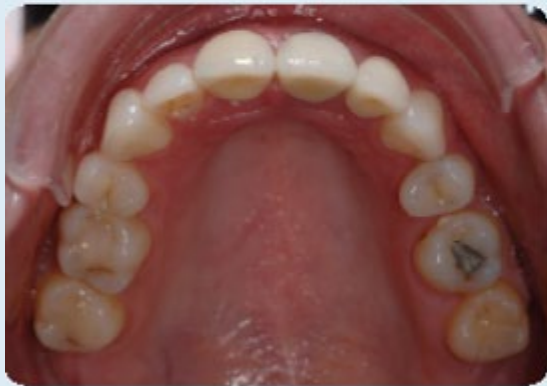
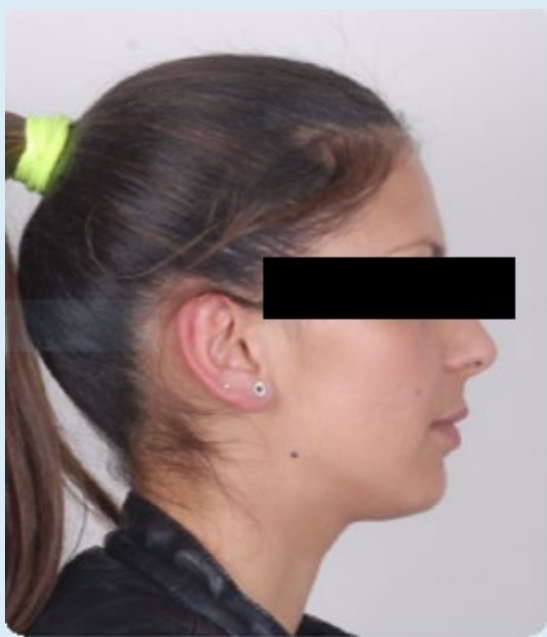


**Laboratory preparation
for oral rehabilitation**

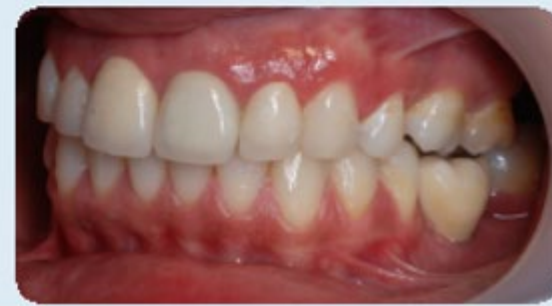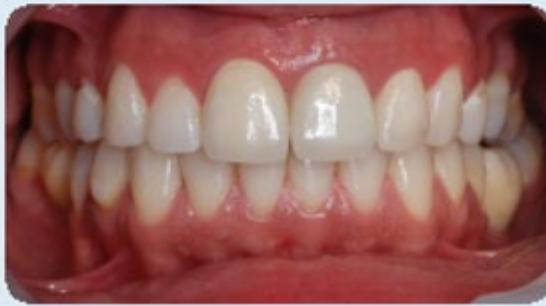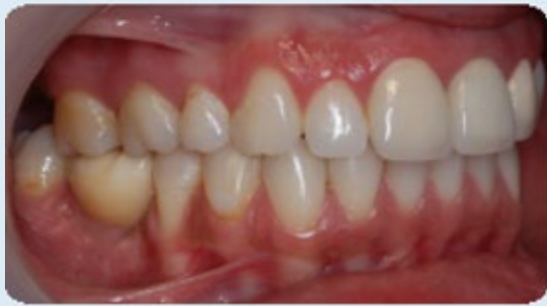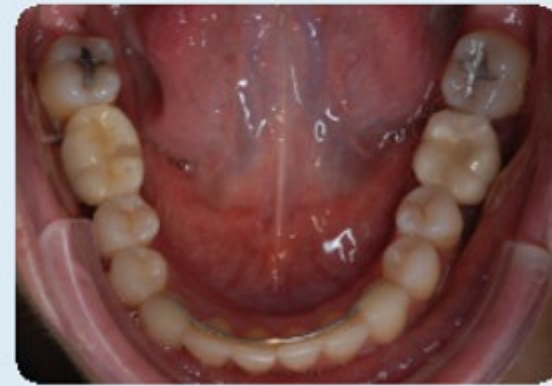**Crowns for implants
Veneers for incisors**

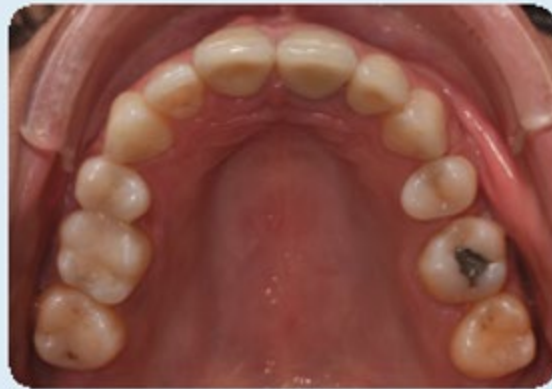
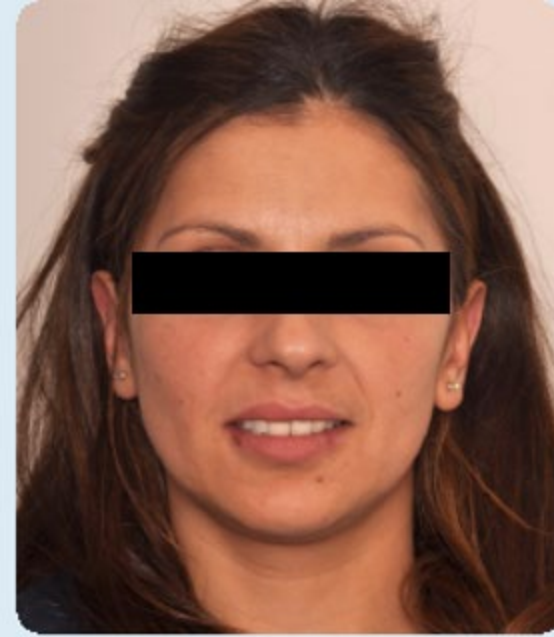
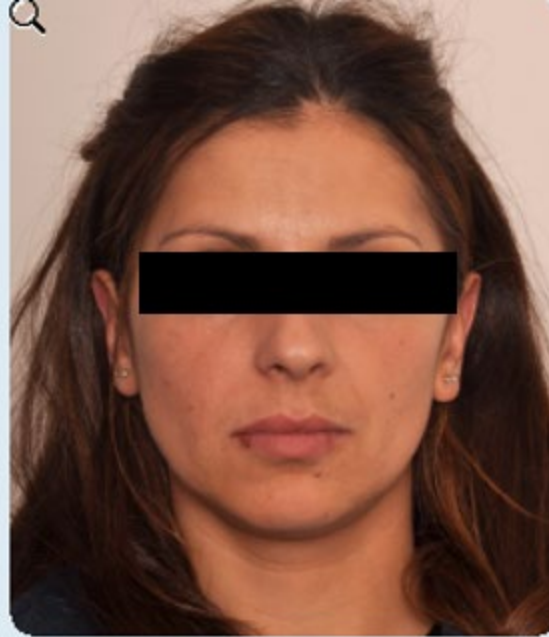
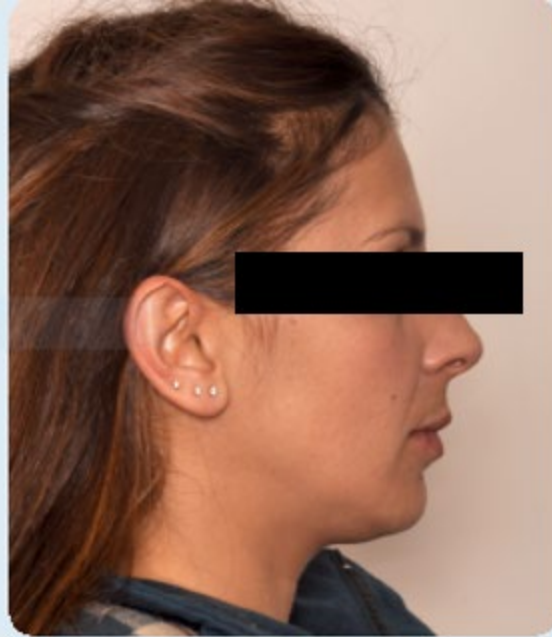
Complex interdisciplinary case

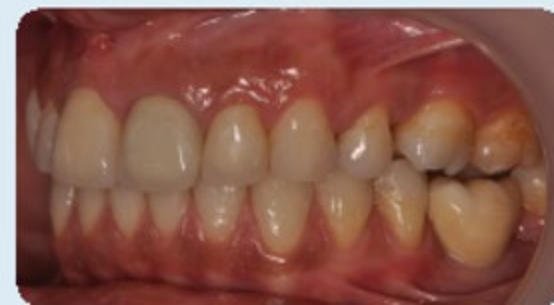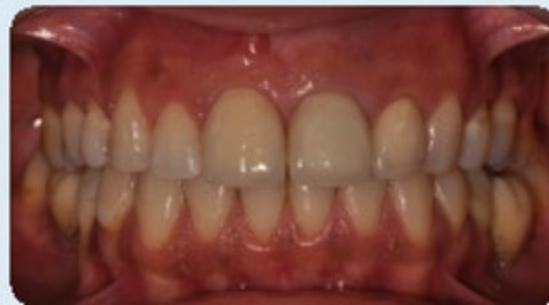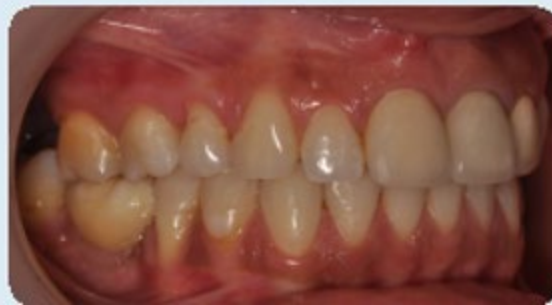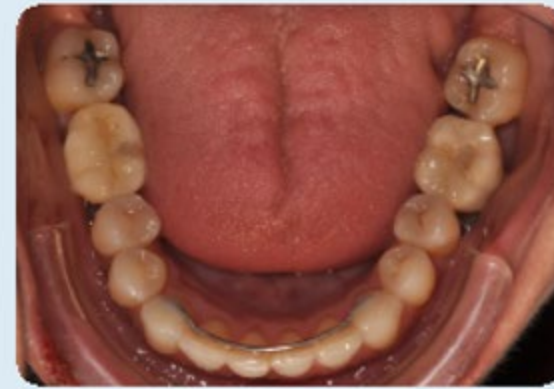FINAL

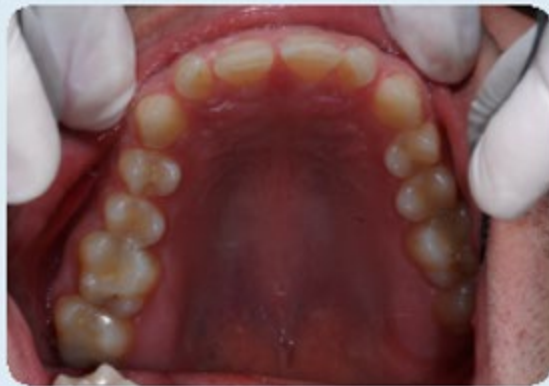
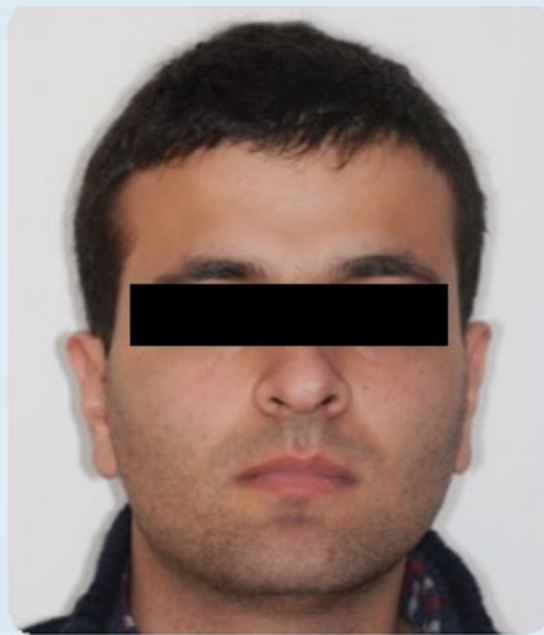
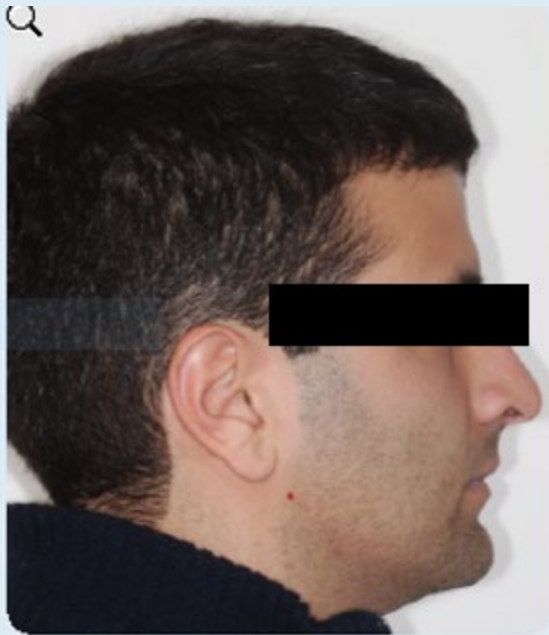

Complex interdisciplinary case

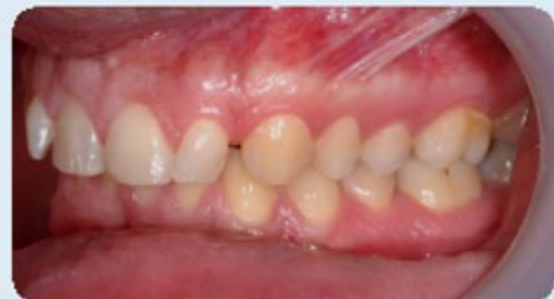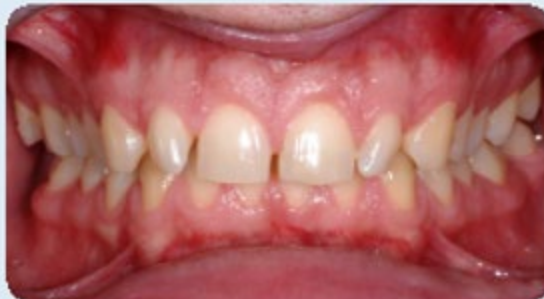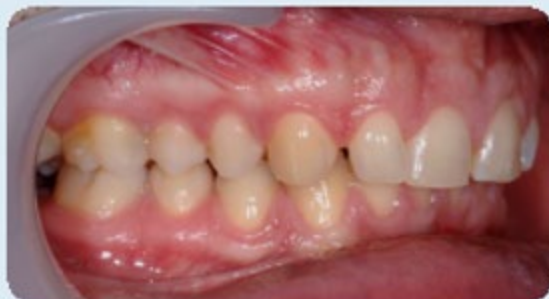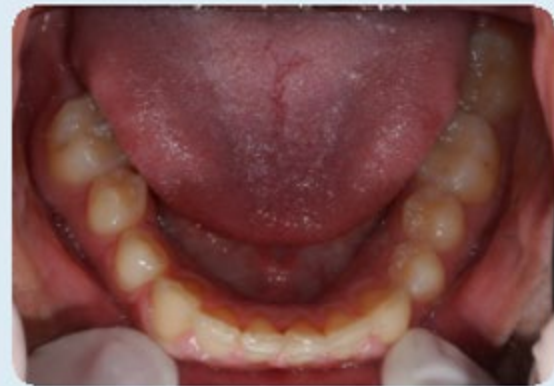3 years after treatment

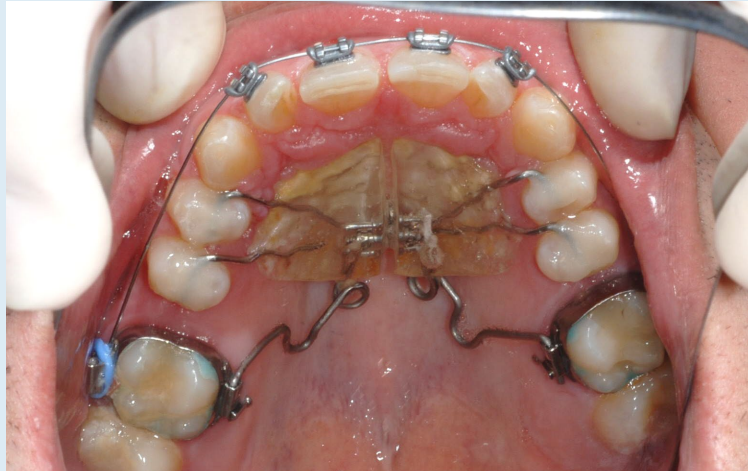
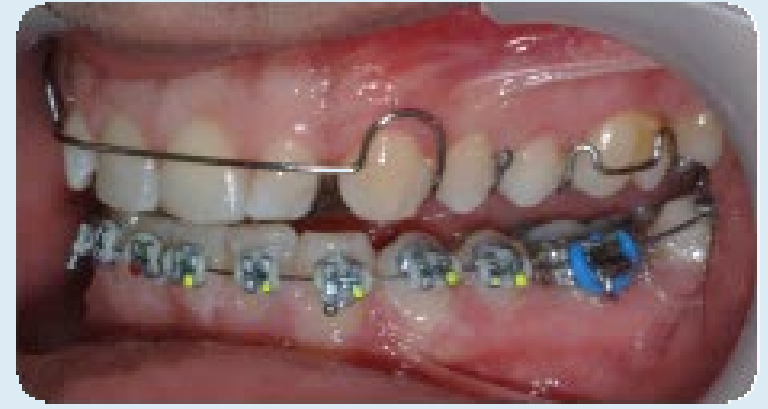
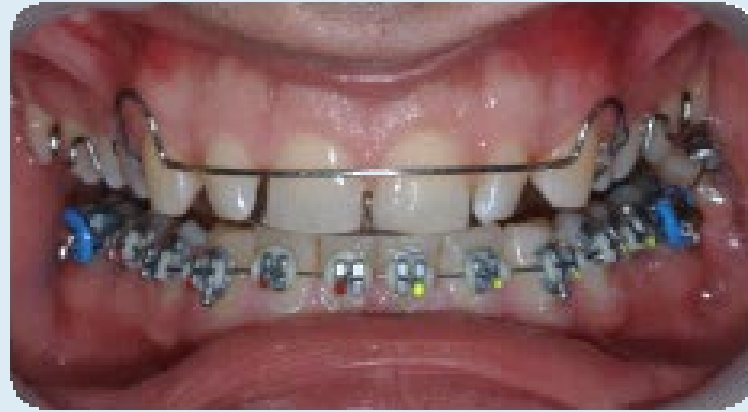
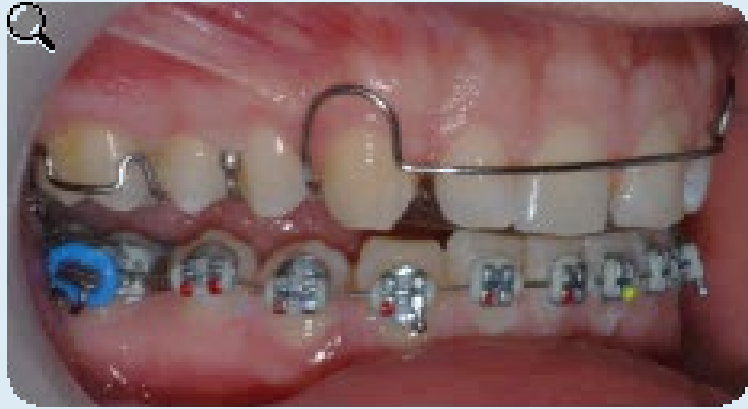

Complex interdisciplinary case

INITIAL

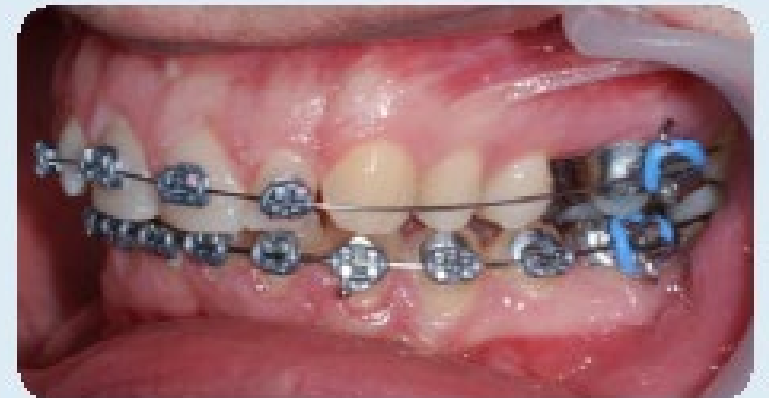
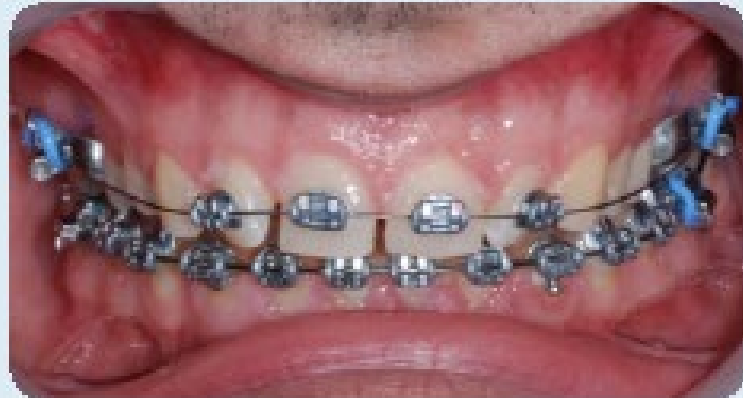
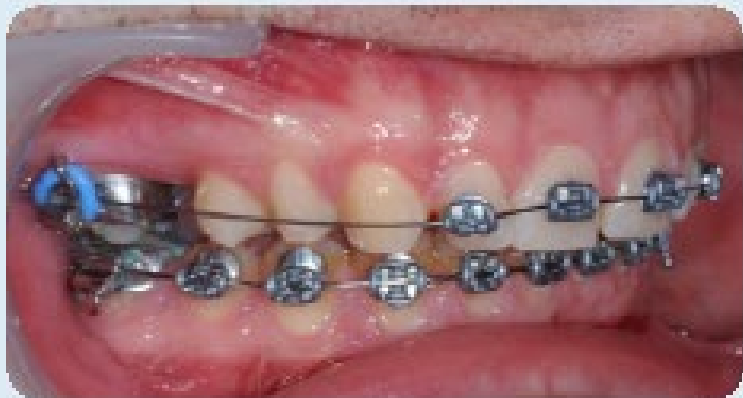

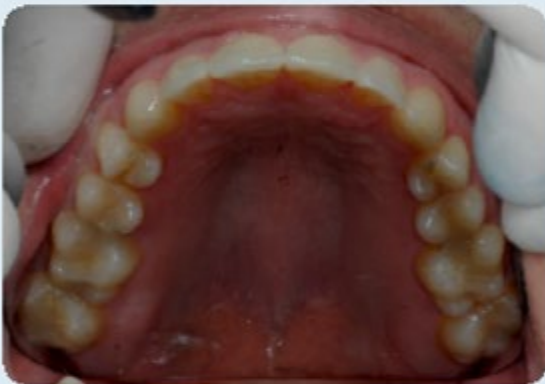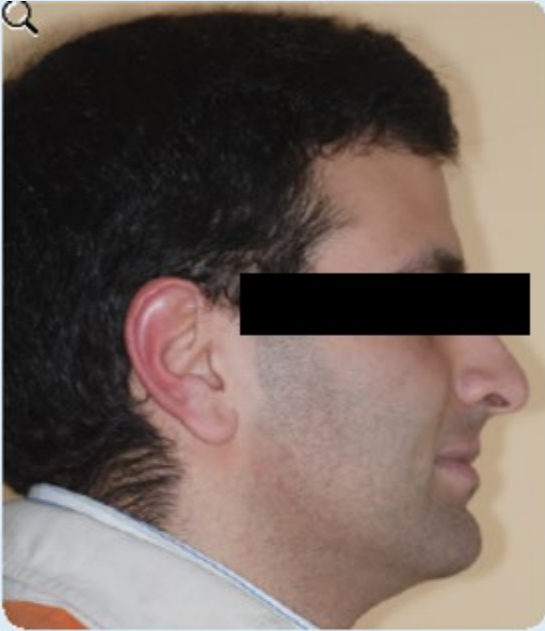Complex interdisciplinary case

PROGRESS

**Orthodontic treatment
with molar distalization**





Complex interdisciplinary case

FINAL

Orthodontic treatment, ceramic veneers in the upper incisors

