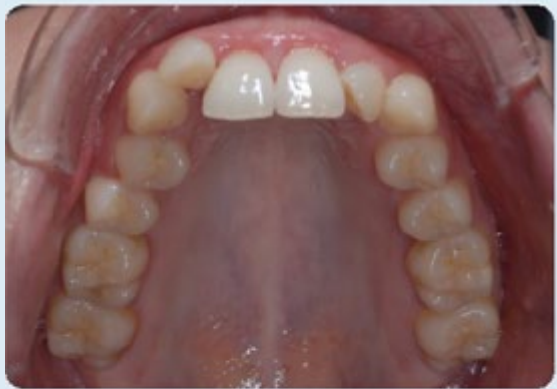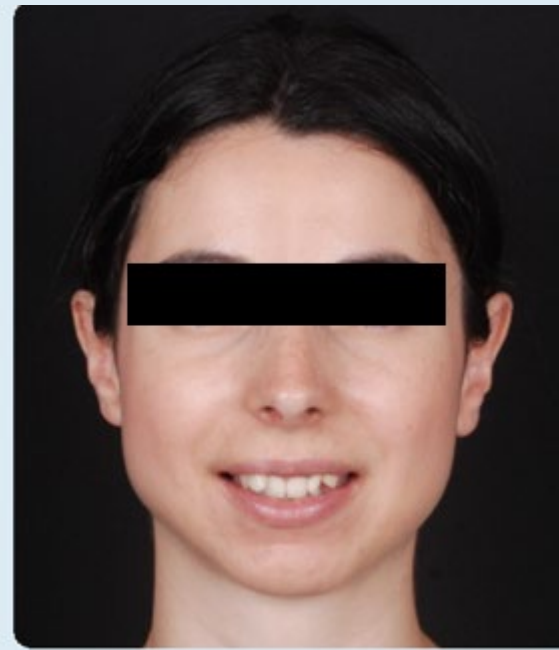

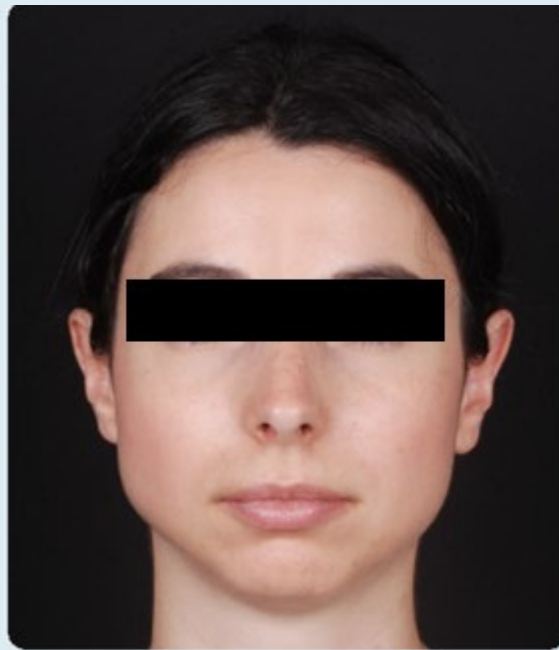
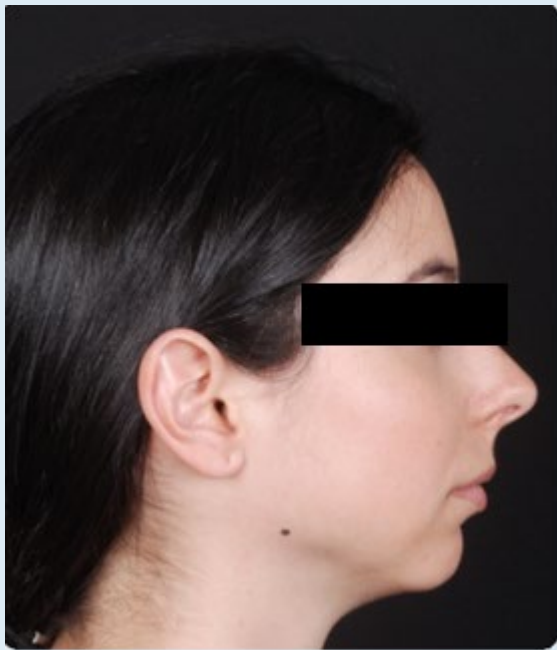

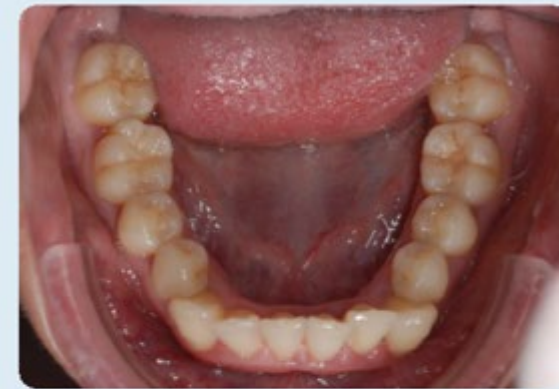Ορθοπρόνοα

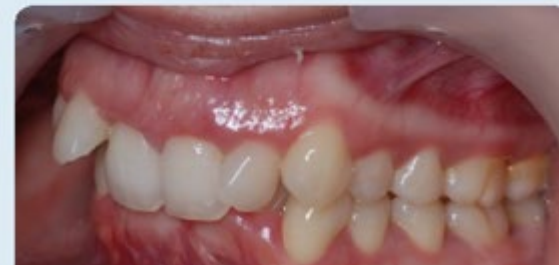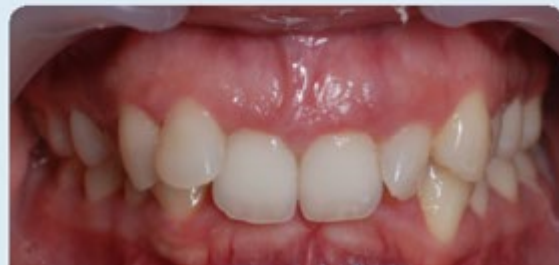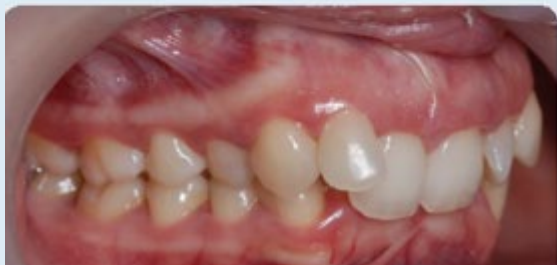Dentofacial deformity
Class II skeletal



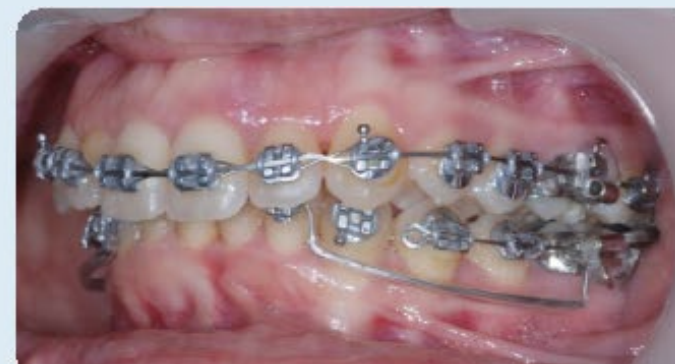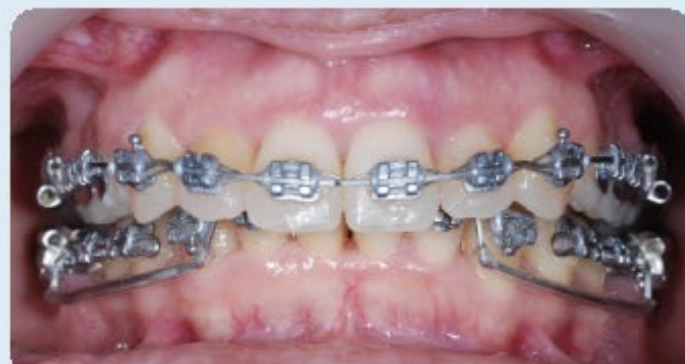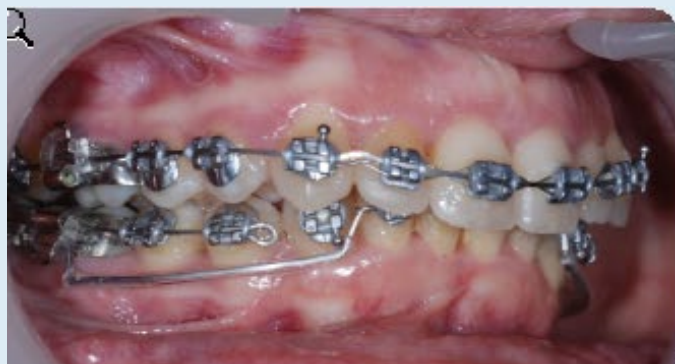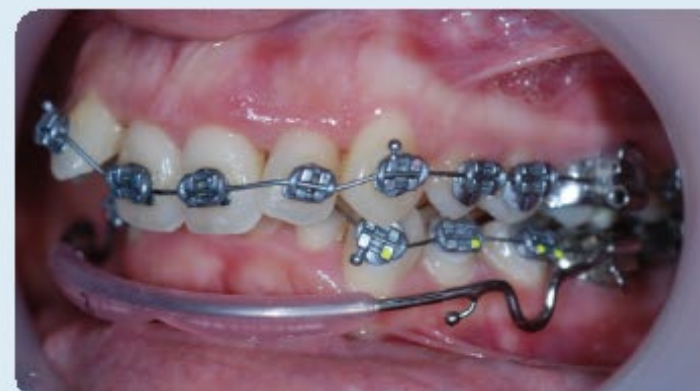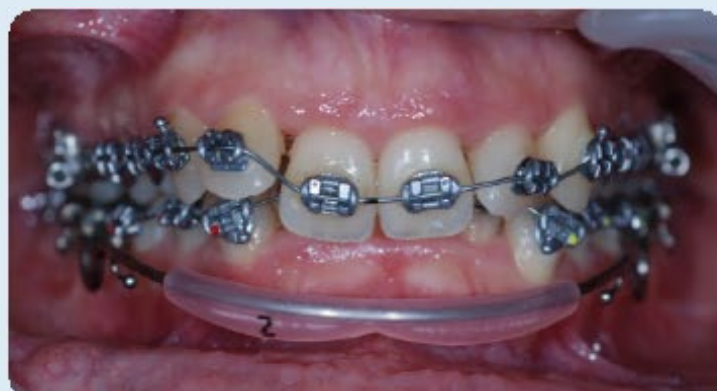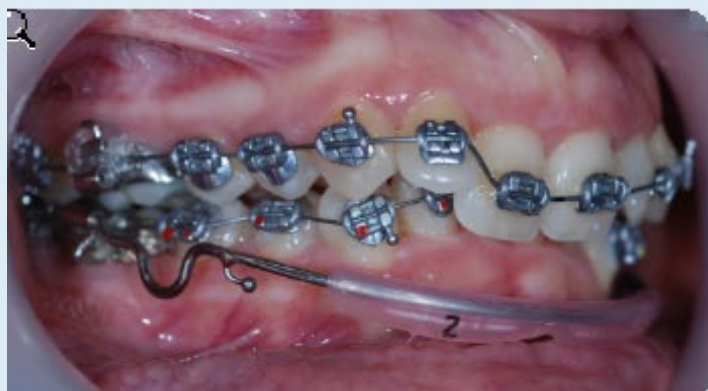**Class II skeletal
Orthodontic-surgical case**

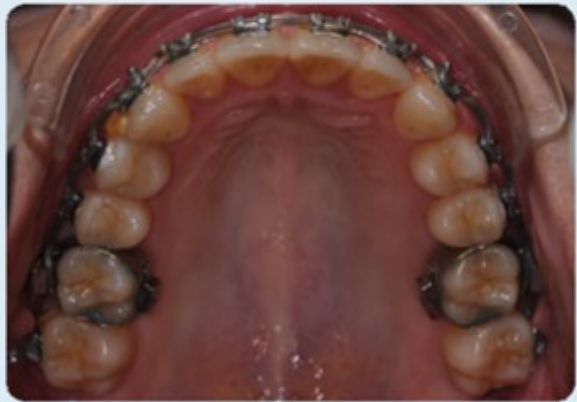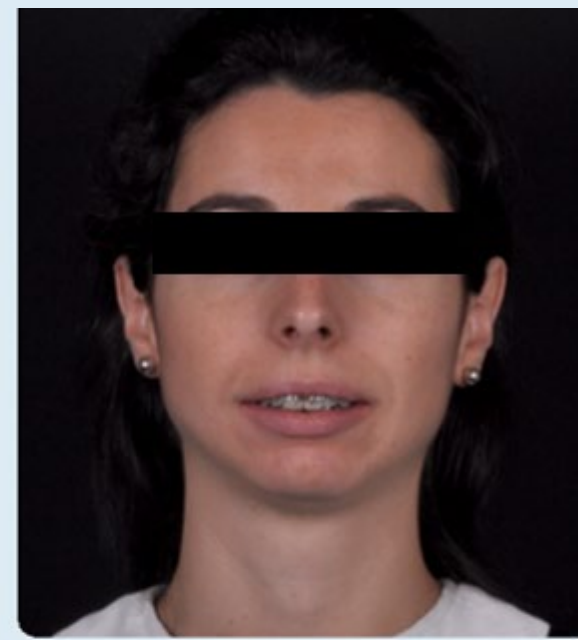

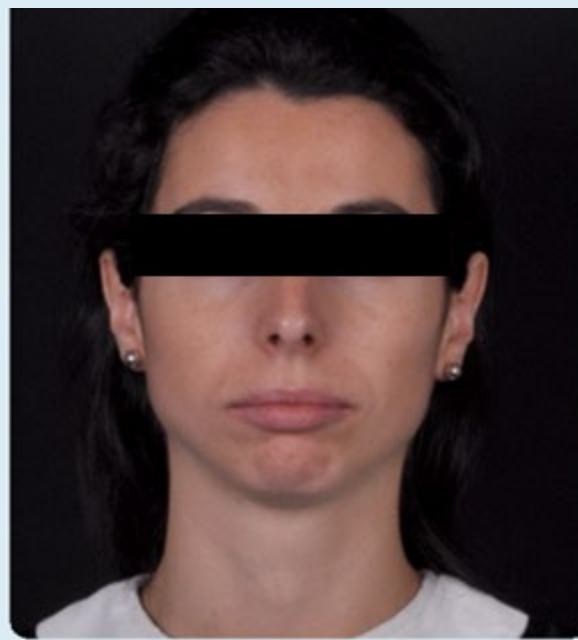
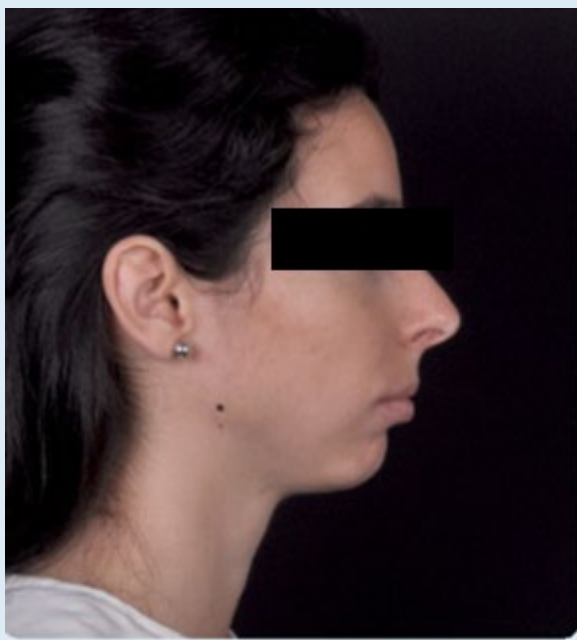initial

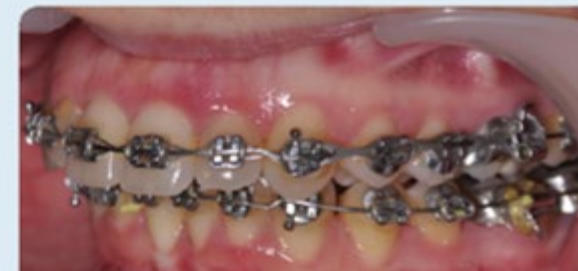
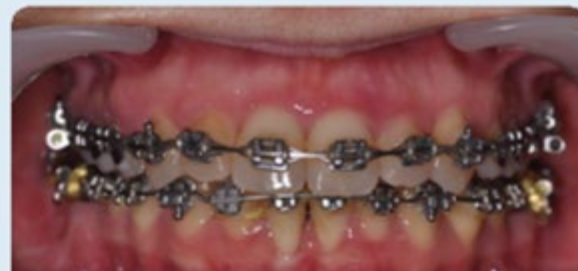
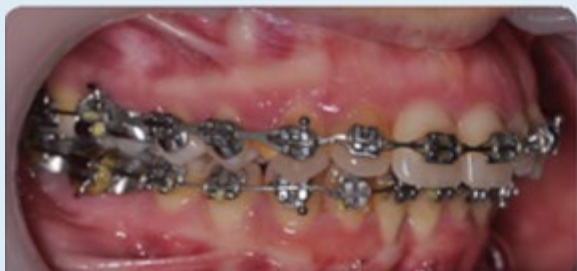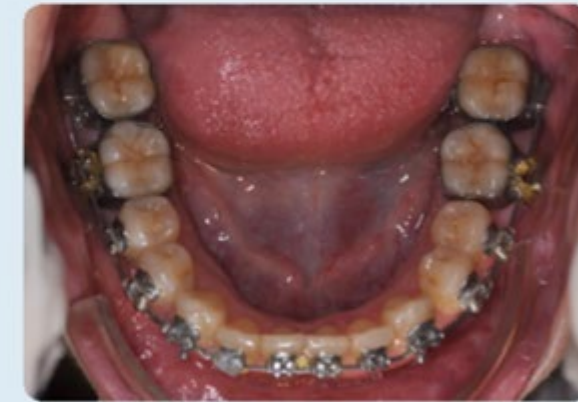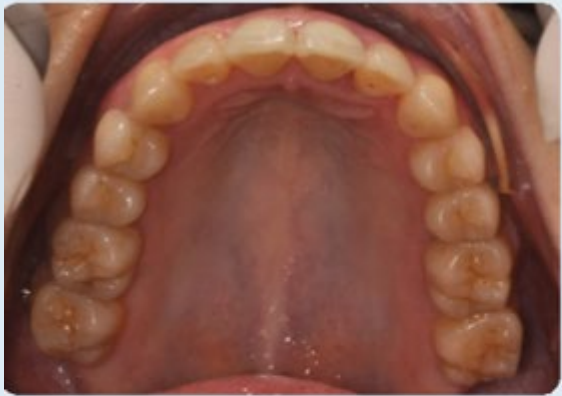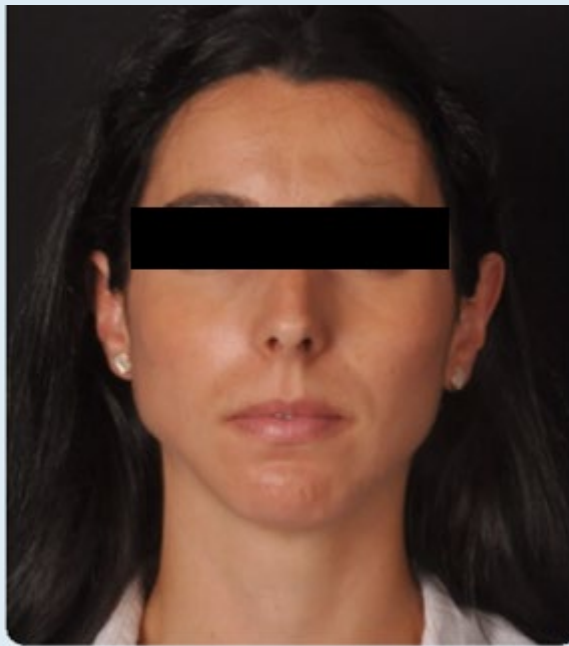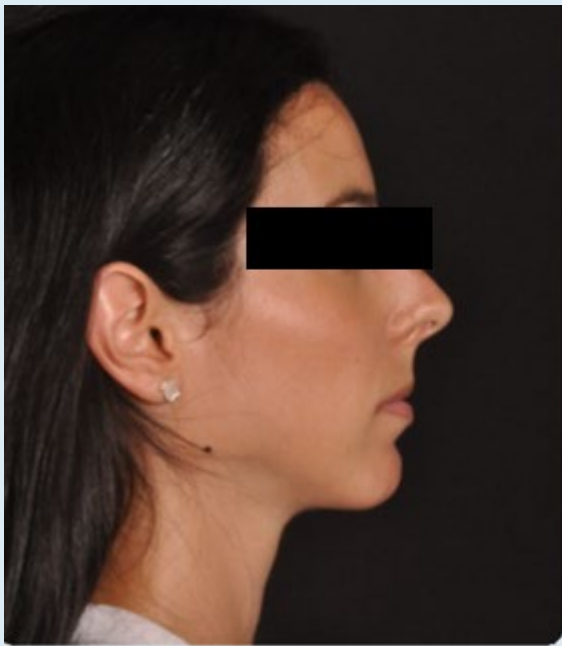Class II skeletal
Orthodontic-surgical case
progress



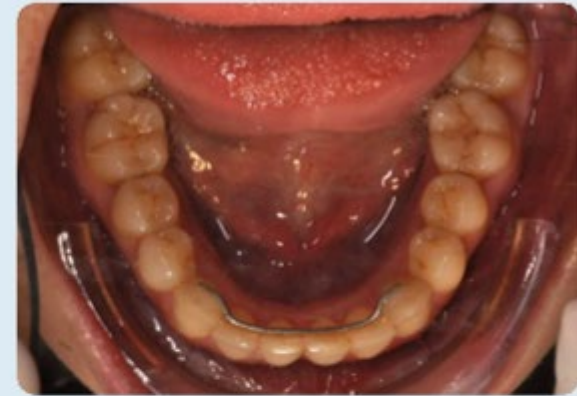

**Class II skeletal
Orthodontic-surgical case
pre-surgical**

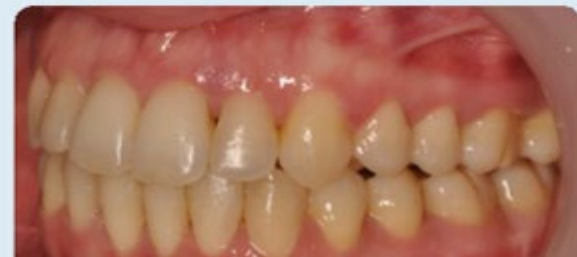
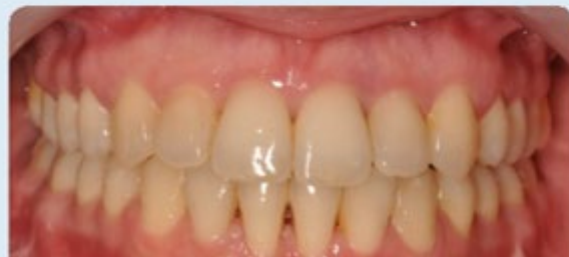
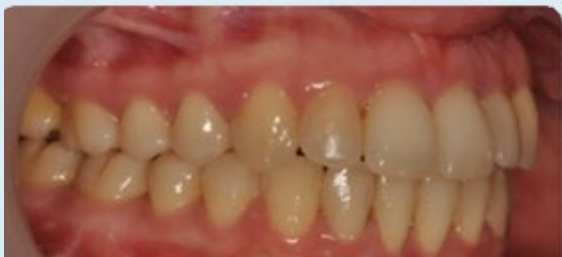

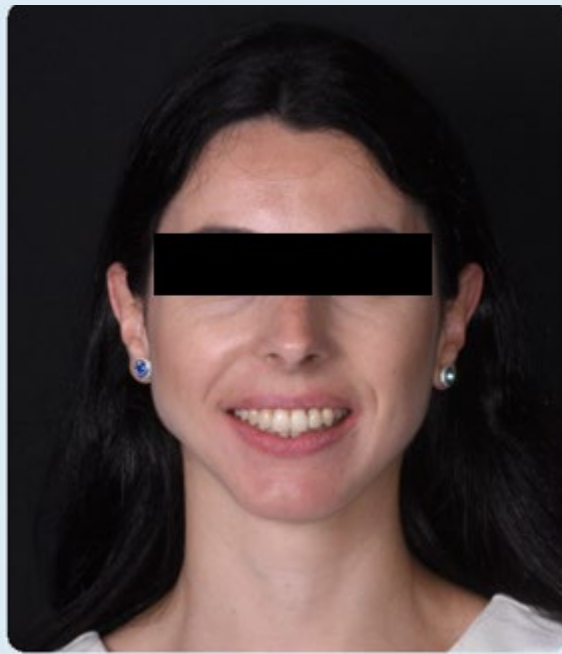**Class II skeletal
Orthodontic-surgical case**



final





Class II skeletal

2 years after
treatment

