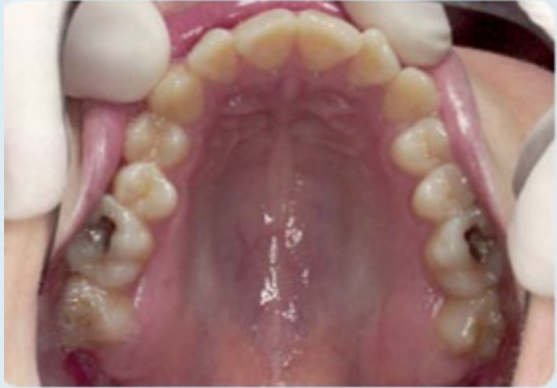
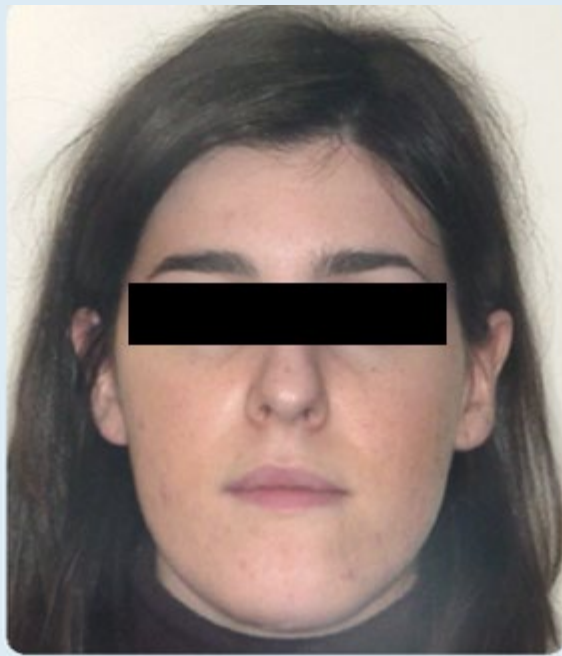
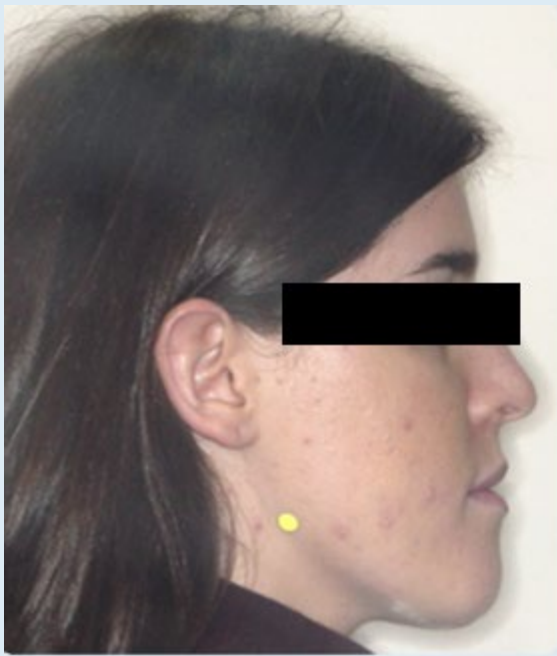

Ορθοπόνοα

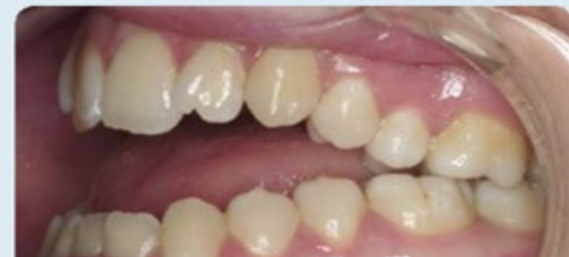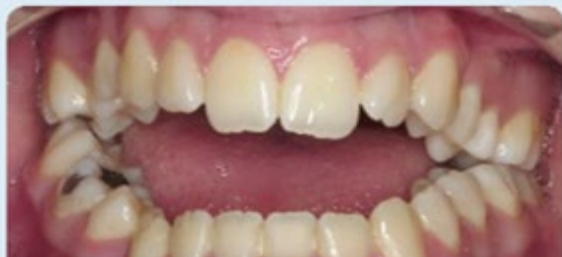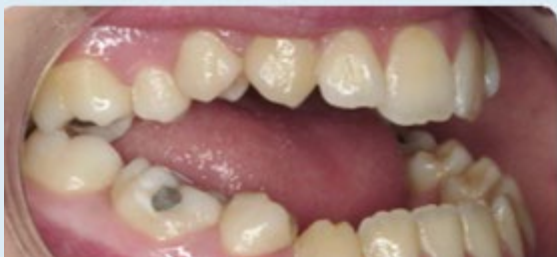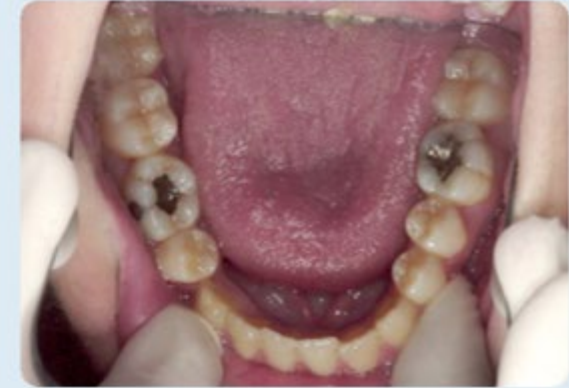Dentofacial deformity  
skeletal anterior  
open-bite



**Skeletal anterior open-bite**

**Orthodontic-surgical case**

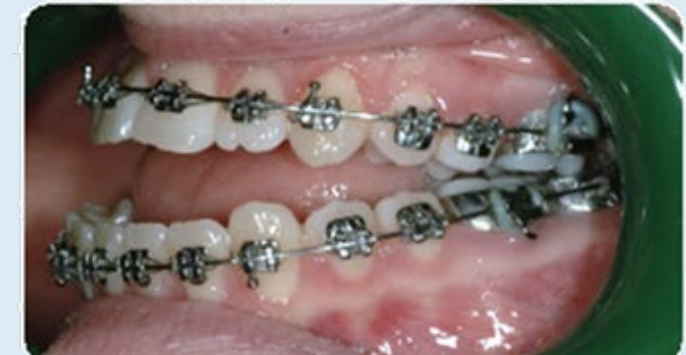
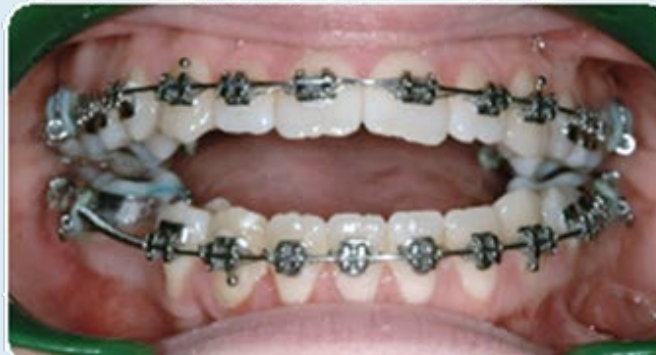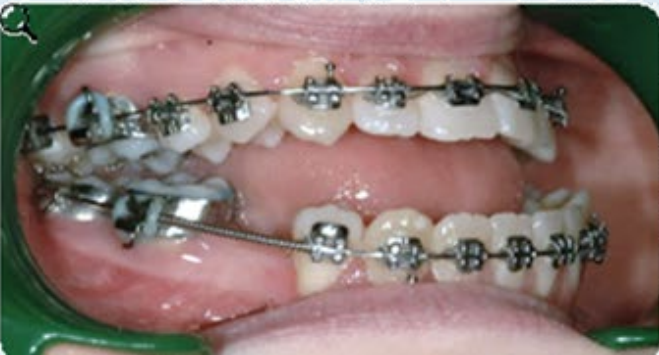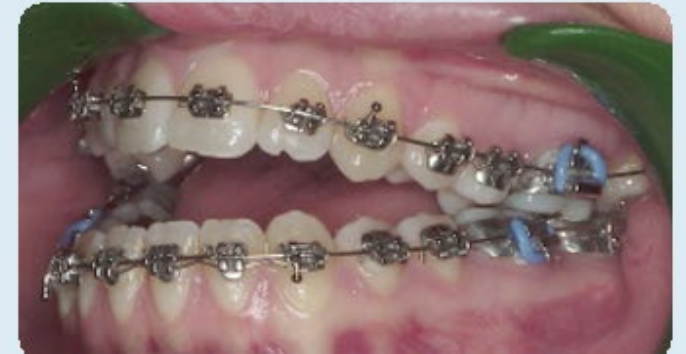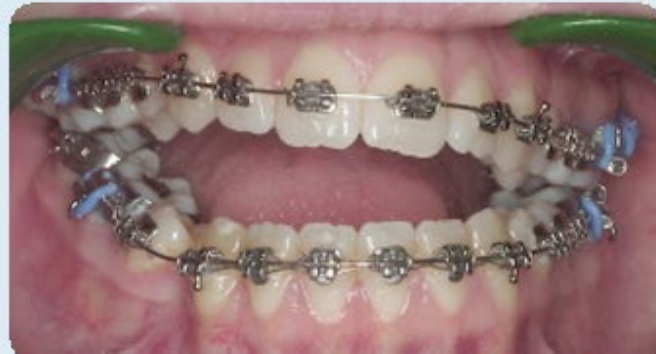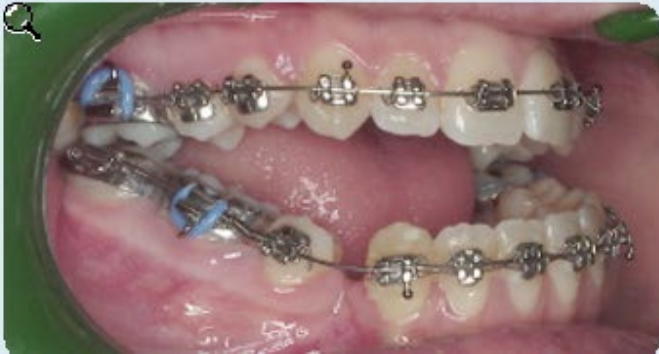**initial**



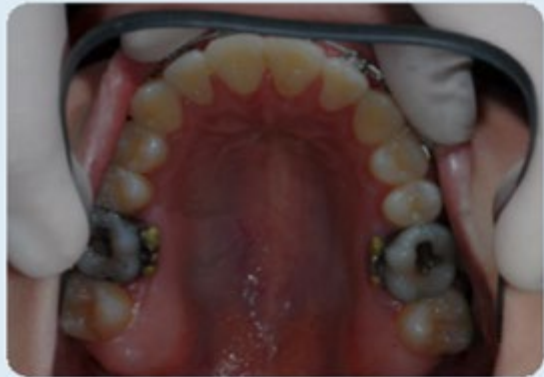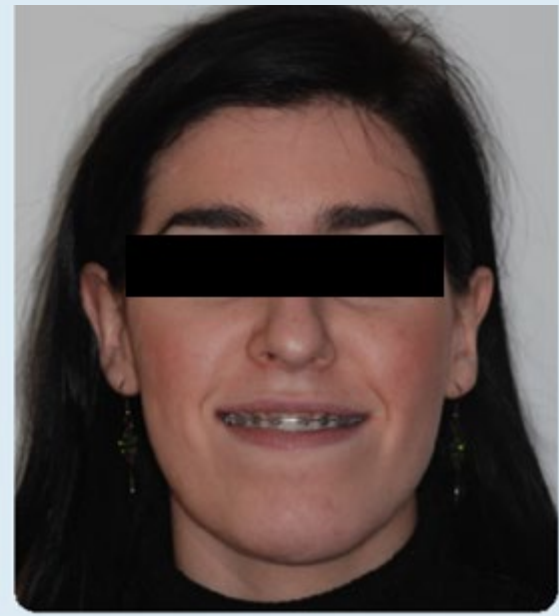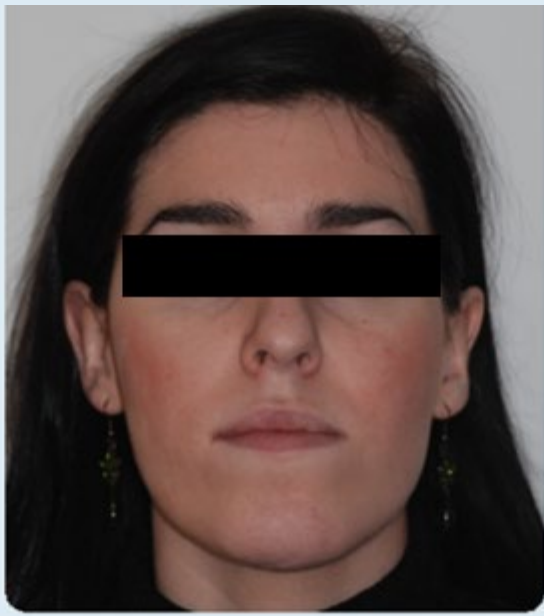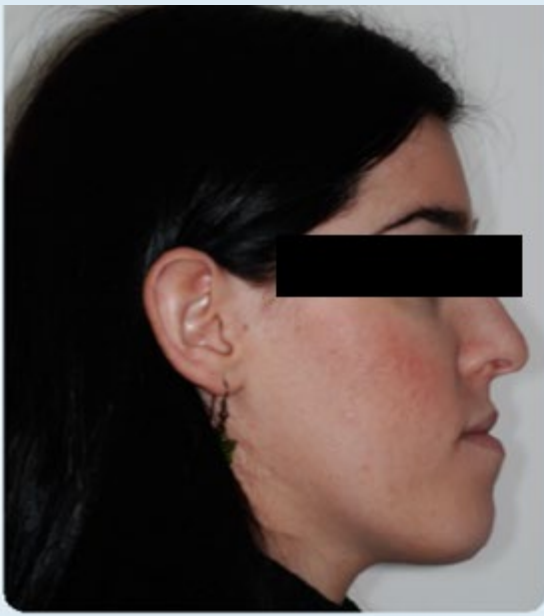Skeletal anterior open-bite

Orthodontic-surgical case

progress



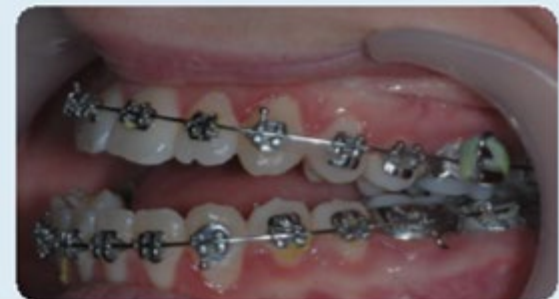
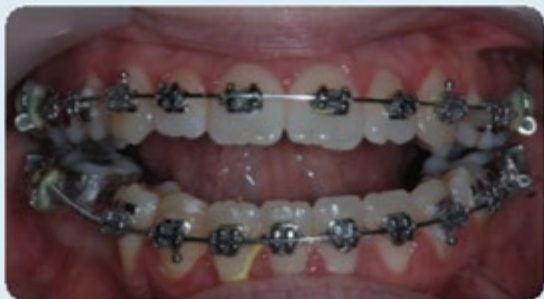
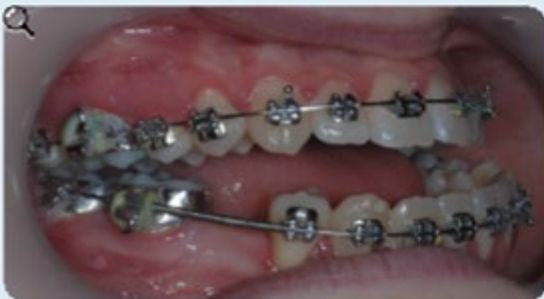
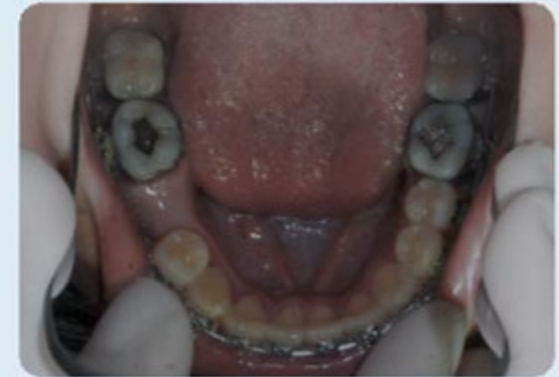
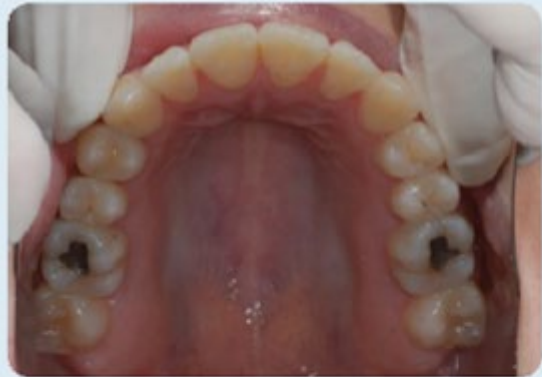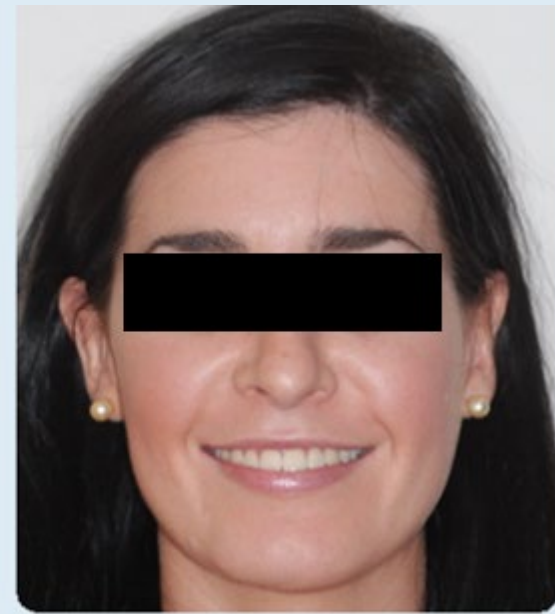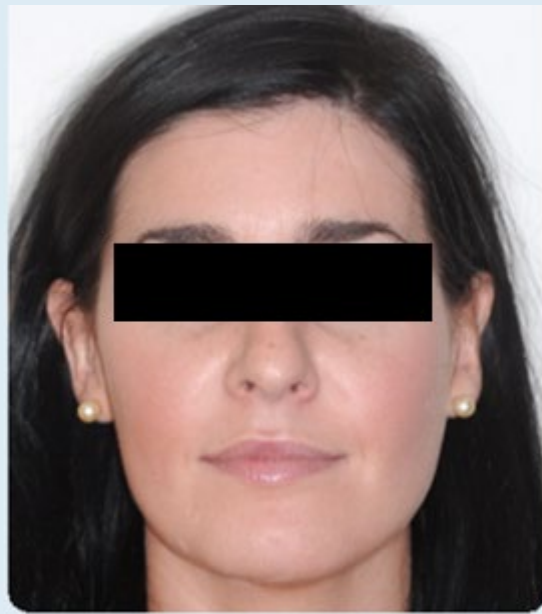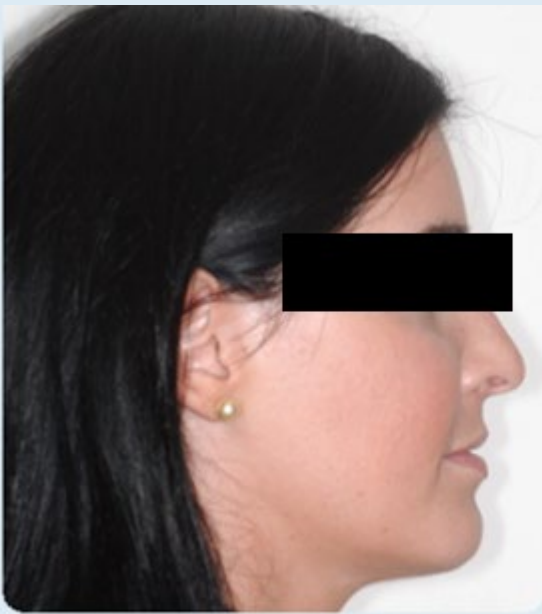**Skeletal anterior open-bite**

**Orthodontic-surgical case**

**pre-surgical**

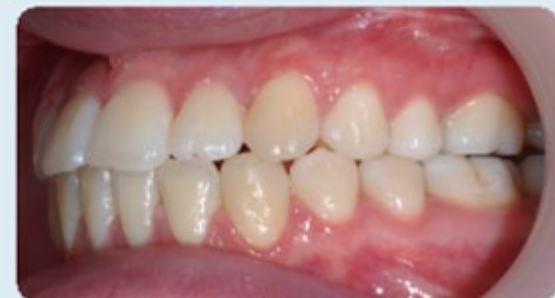
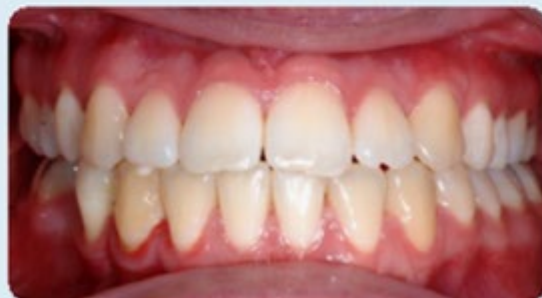
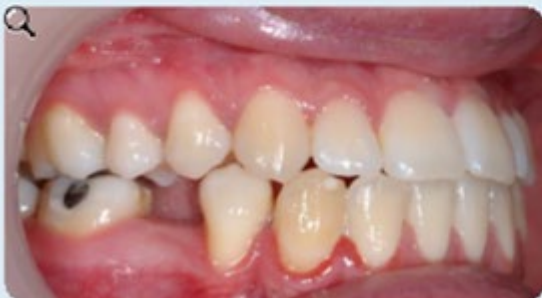
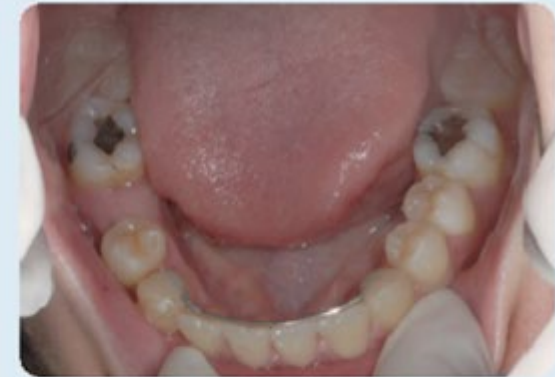
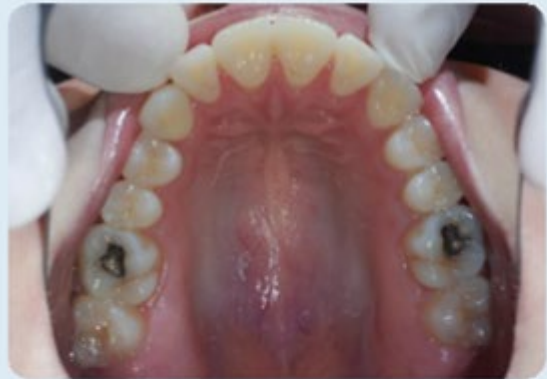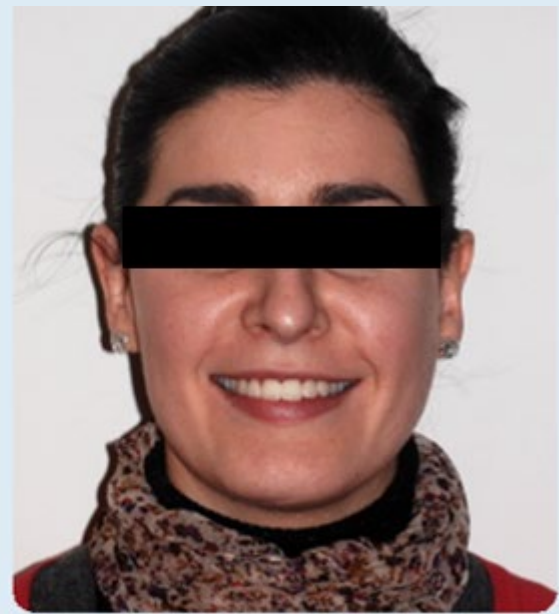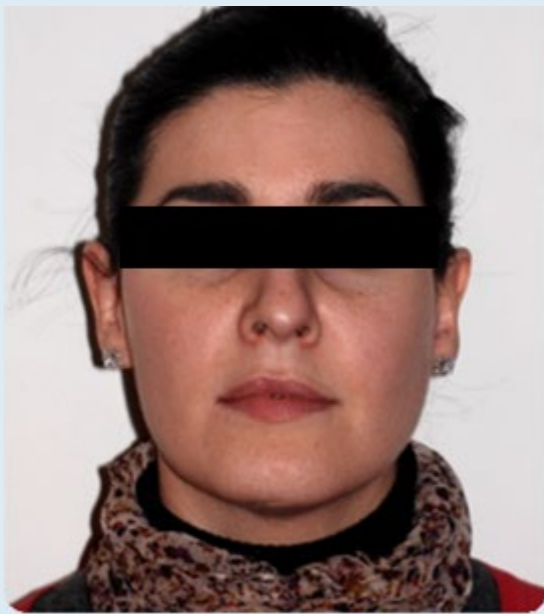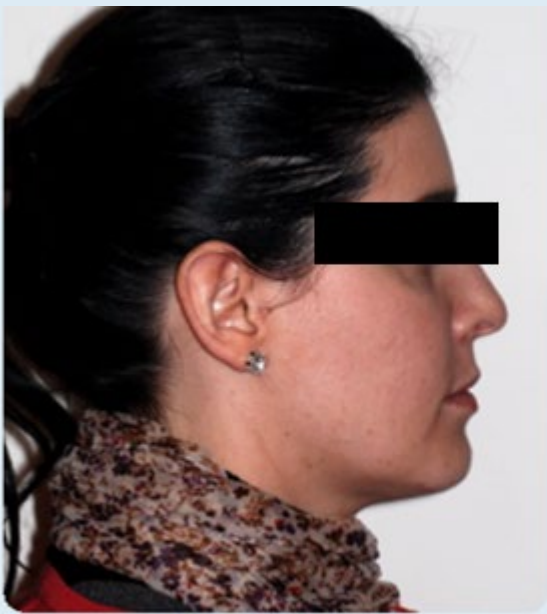**Skeletal anterior open-bite**

**Orthodontic-surgical case**

**final**







Skeletal anterior open-bite

2 years after  
treatment

